

BIOL 213
Blood Pathology

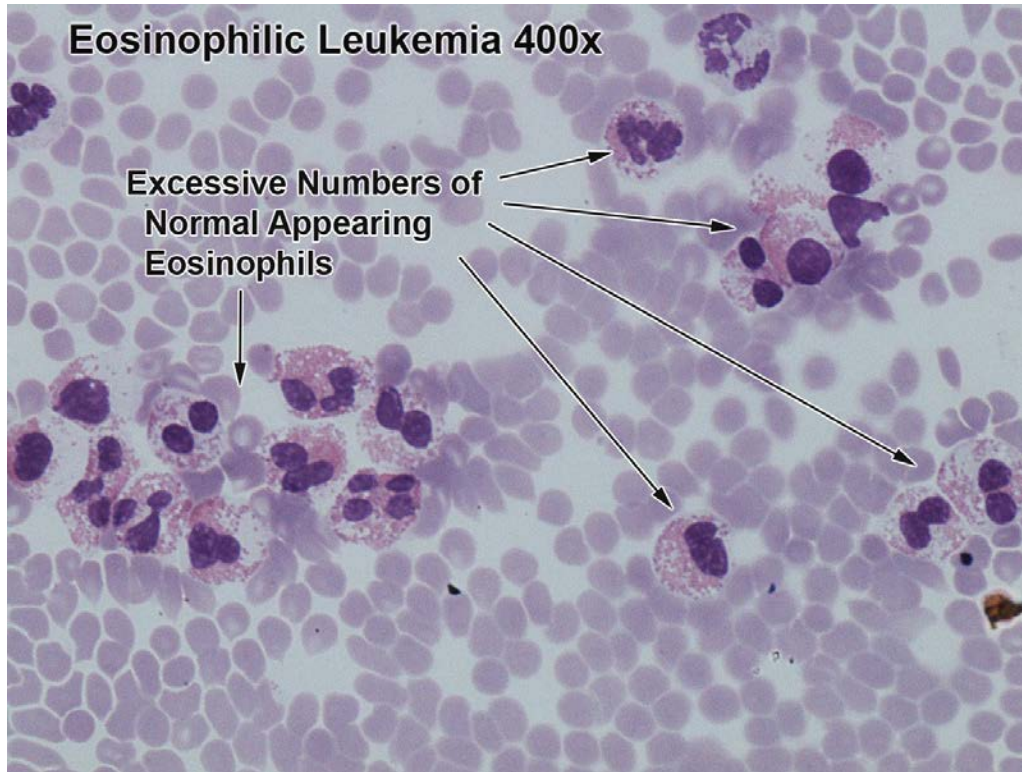
Use the following pictures to help you identify terms from the lab term handout.

***You always only need to know the terms listed in the lab term handout!

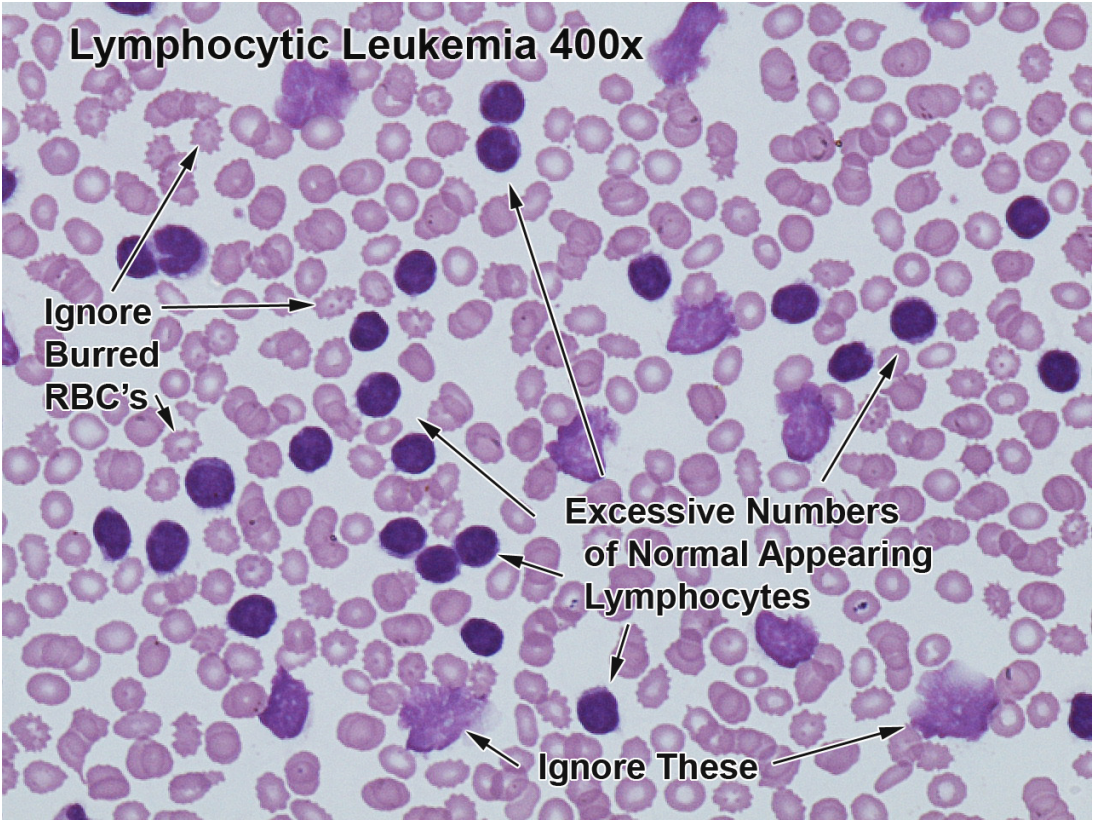
Another good resource for histology is the Olexik website:
http://faculty.montgomerycollege.edu/wolexik/204_histology_page.htm

***Learn about the different pathologies for BONUS on the midterm.

Eosinophilic Leukemia



Lymphocytic Leukemia



Myeloblastic Leukemia

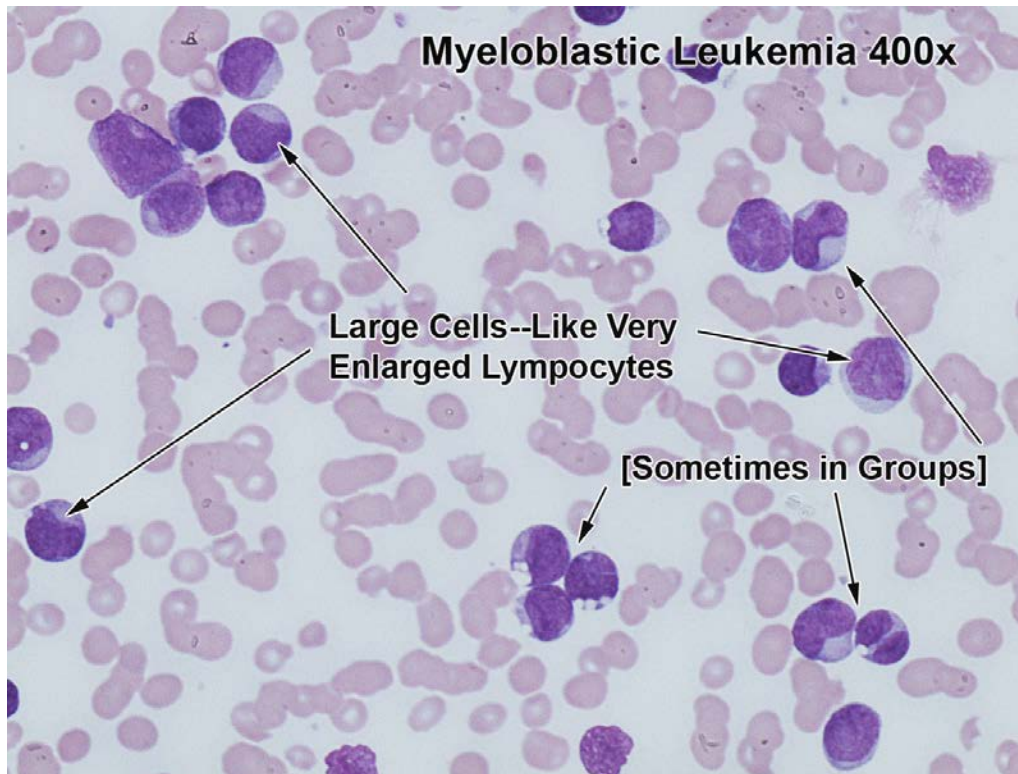
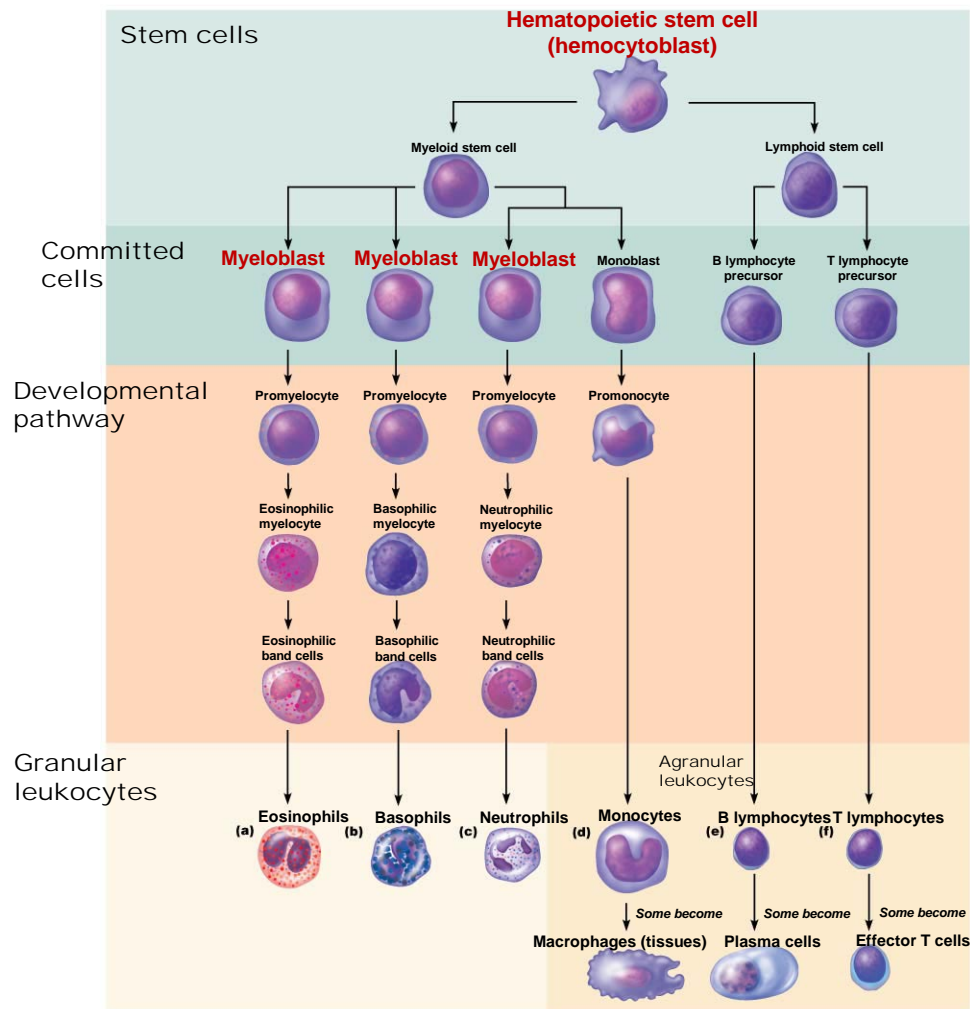
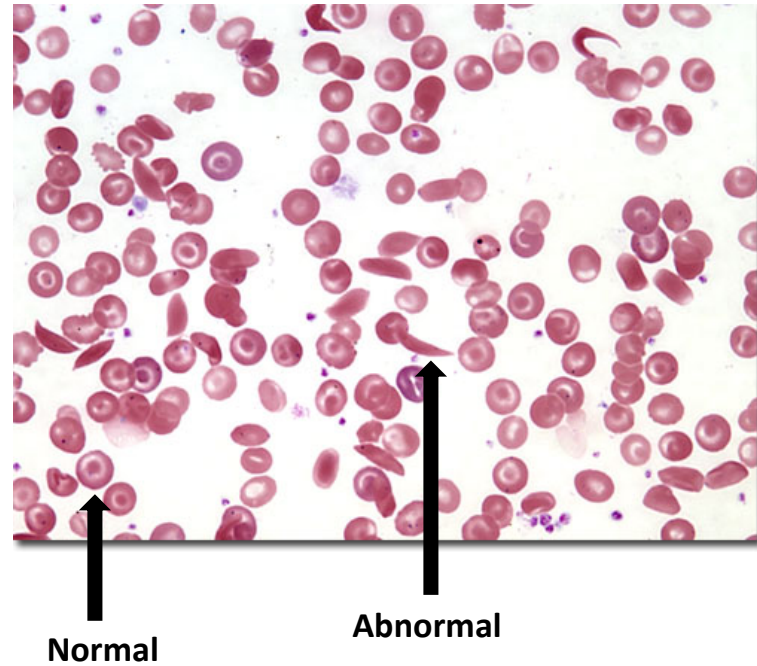


Figure 17.11 Leukocyte formation.

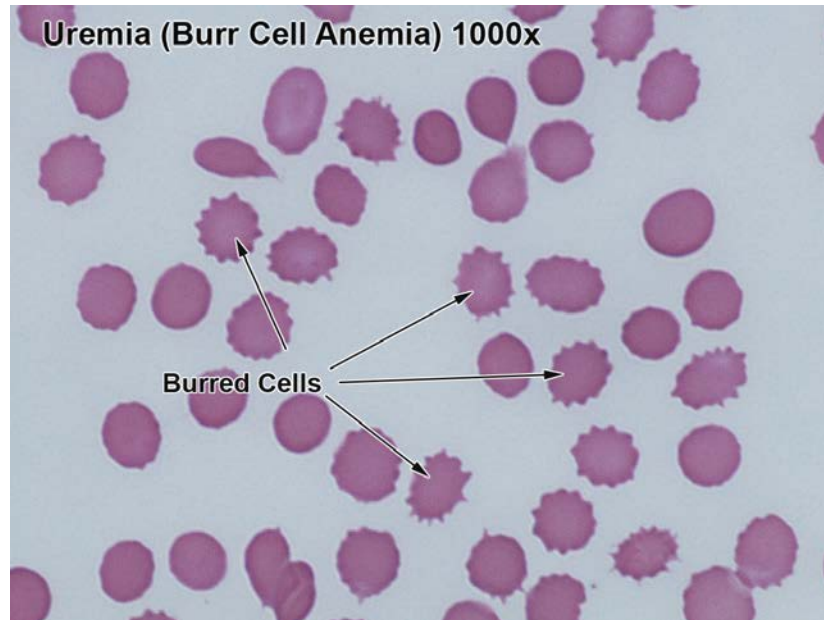


Sickle Cell Anemia

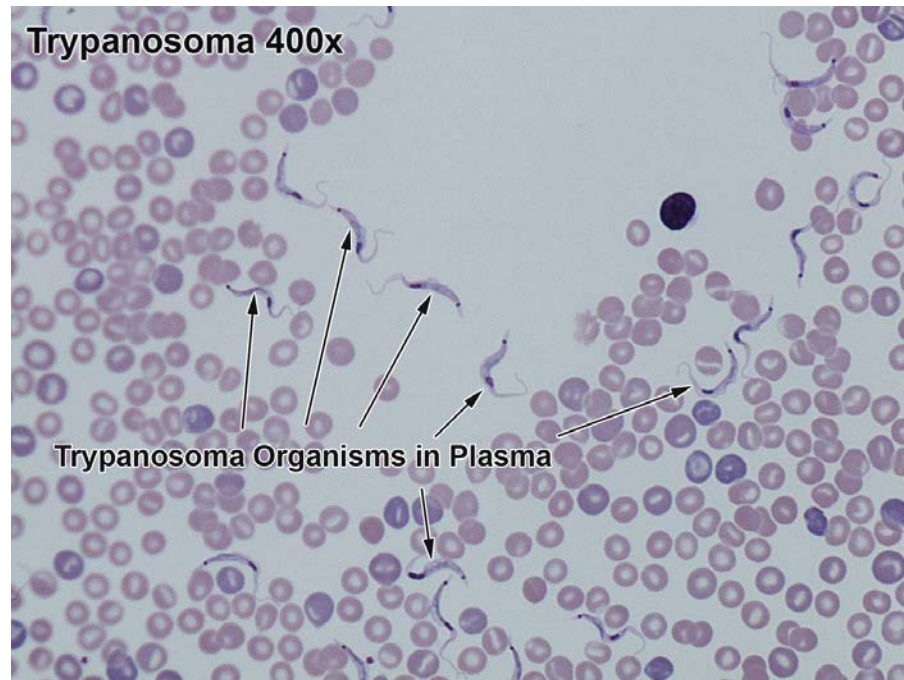


http://www.nhlbi.nih.gov/health/dci/Diseases/Sca/SCA_WhatIs.html - Pathology

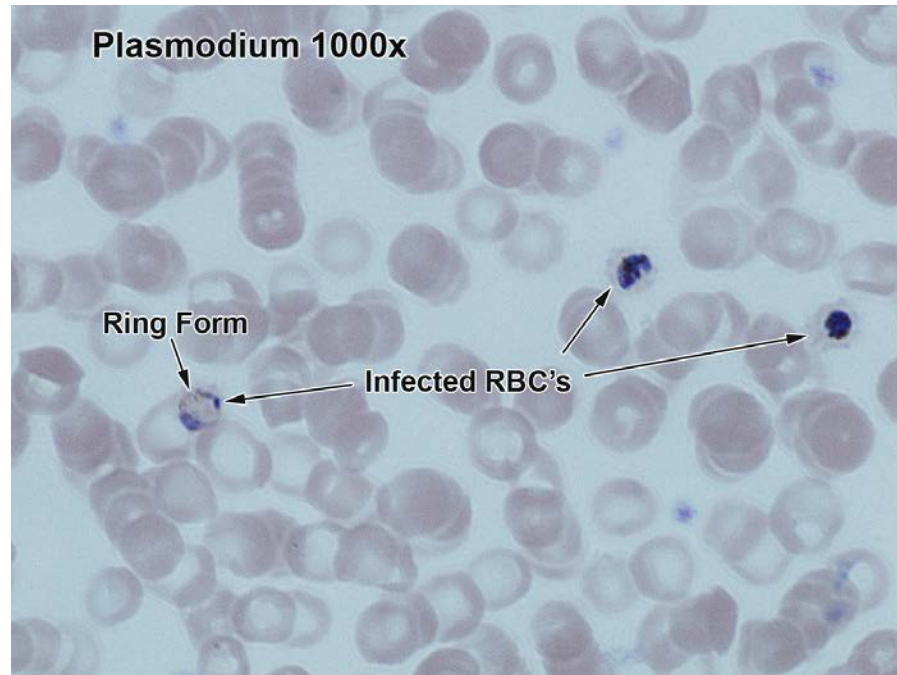
Uremia (Burr Cells)



Trypanosoma

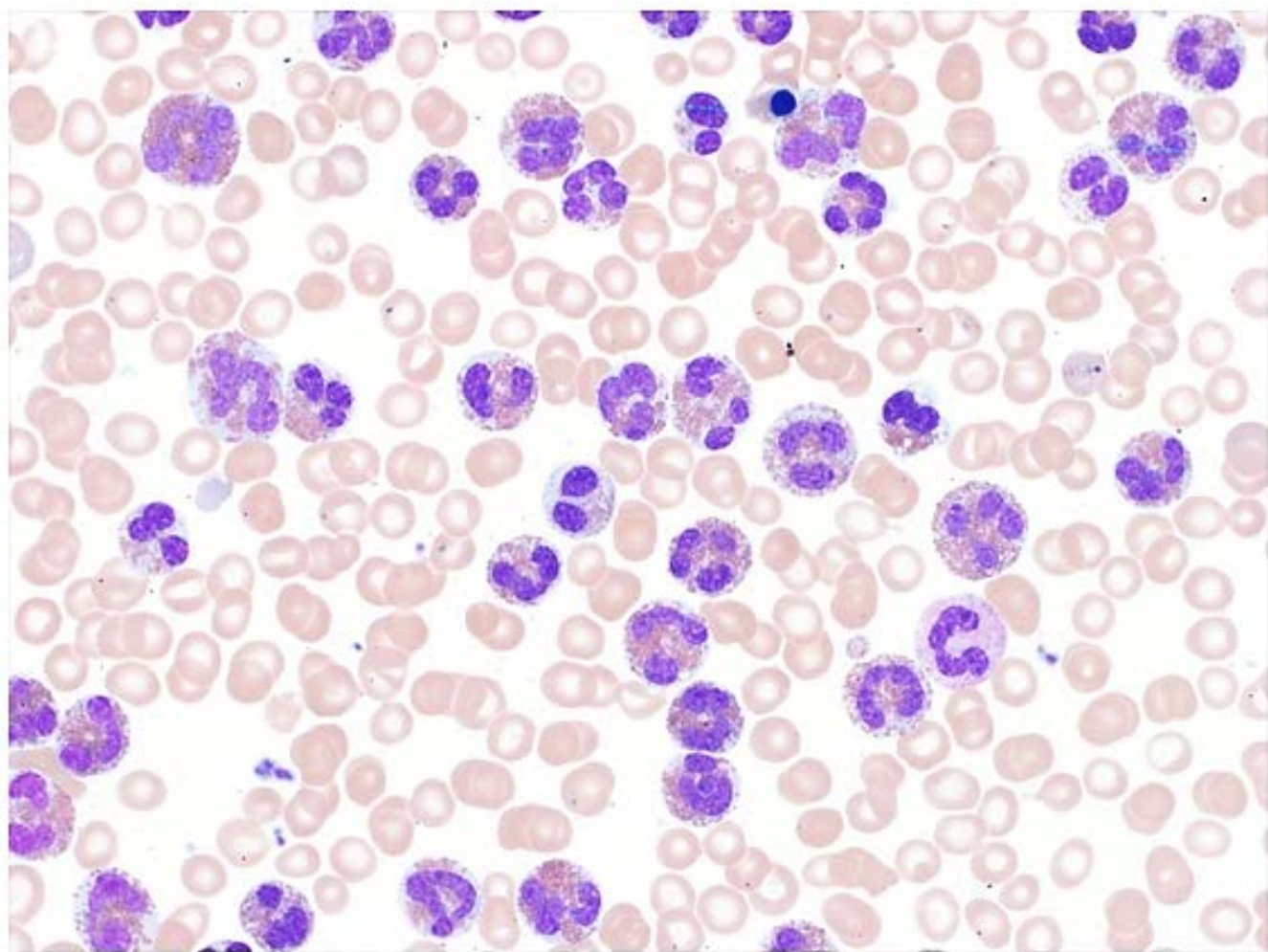


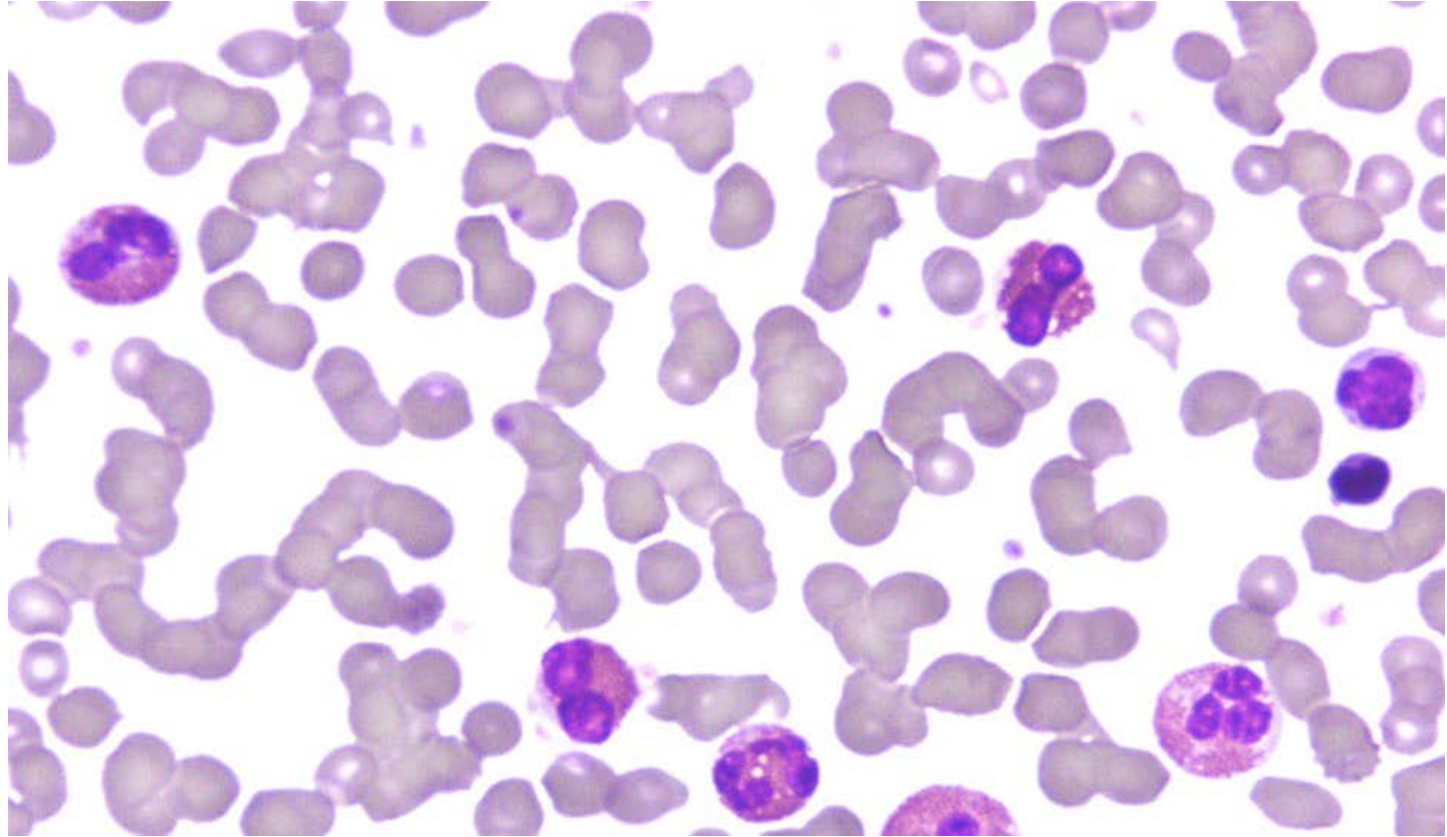
Plasmodium

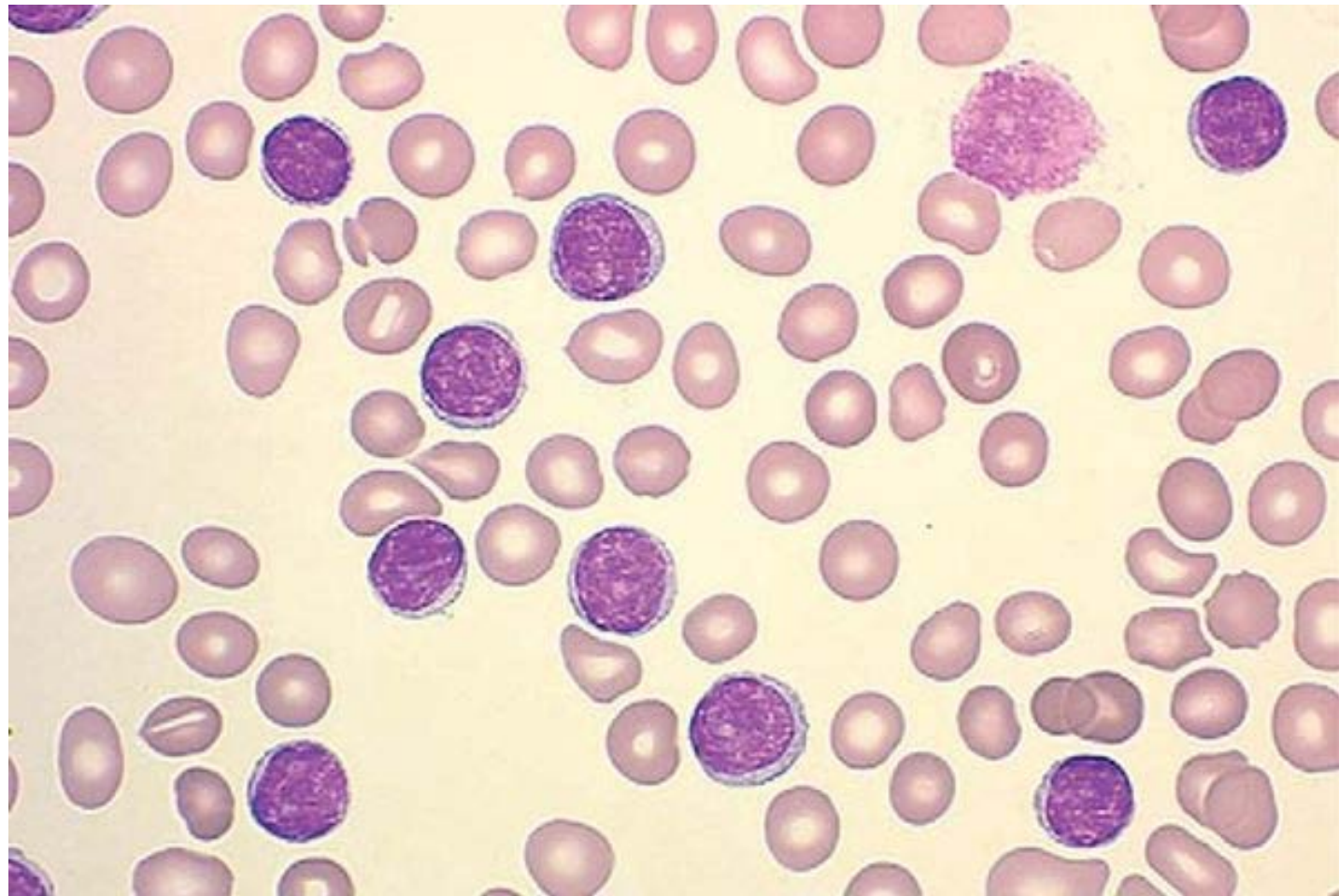


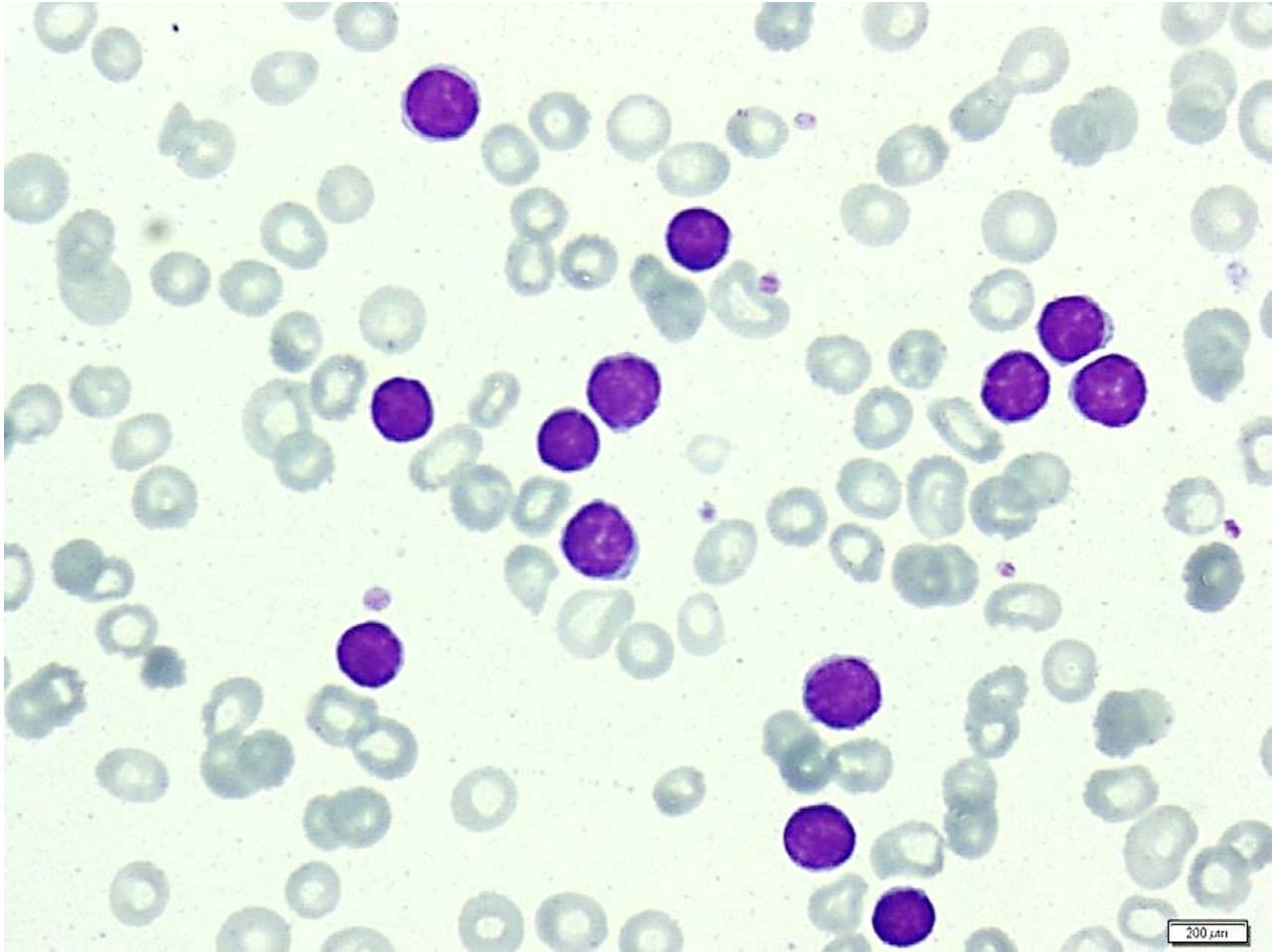
Use the following pictures to help you practice finding the terms from the lab term handout on unlabeled images.

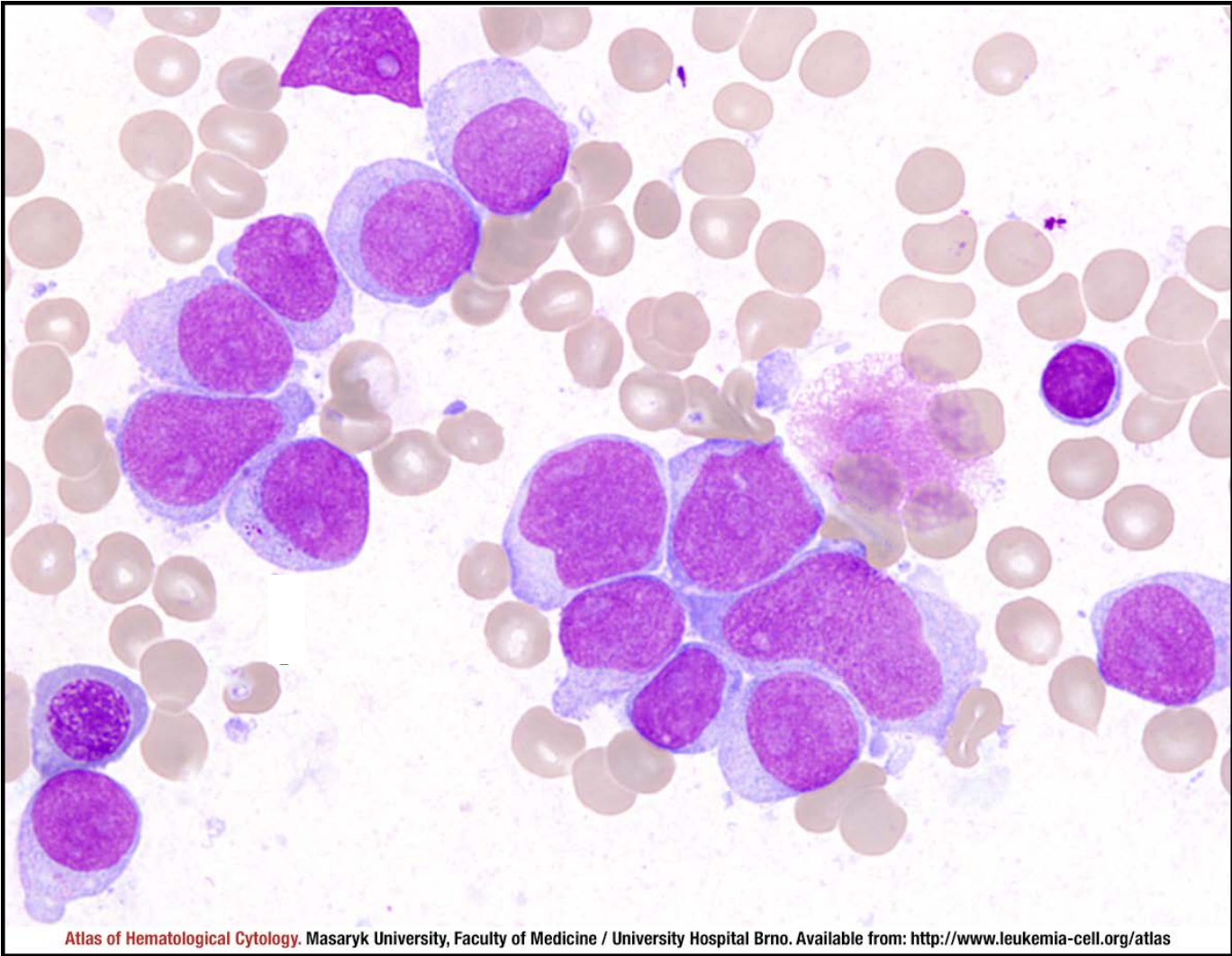
- Remember, you won't learn them if you don't take plenty of time to practice on pictures with NO labels (including no labels for what type of slide it is on histology pictures)!
- Also, be sure to mix up the order once you get comfortable with the unlabeled slides.



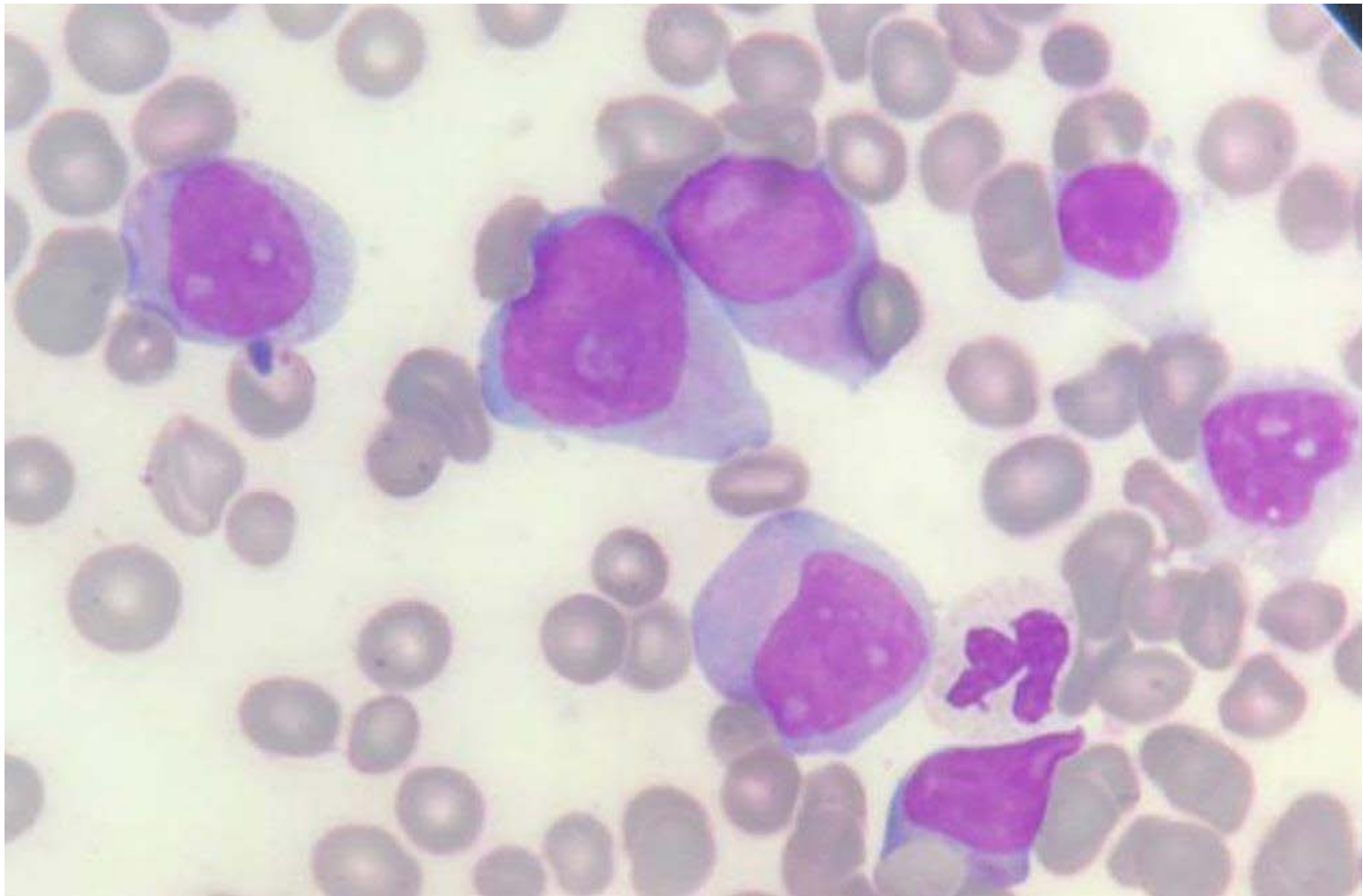


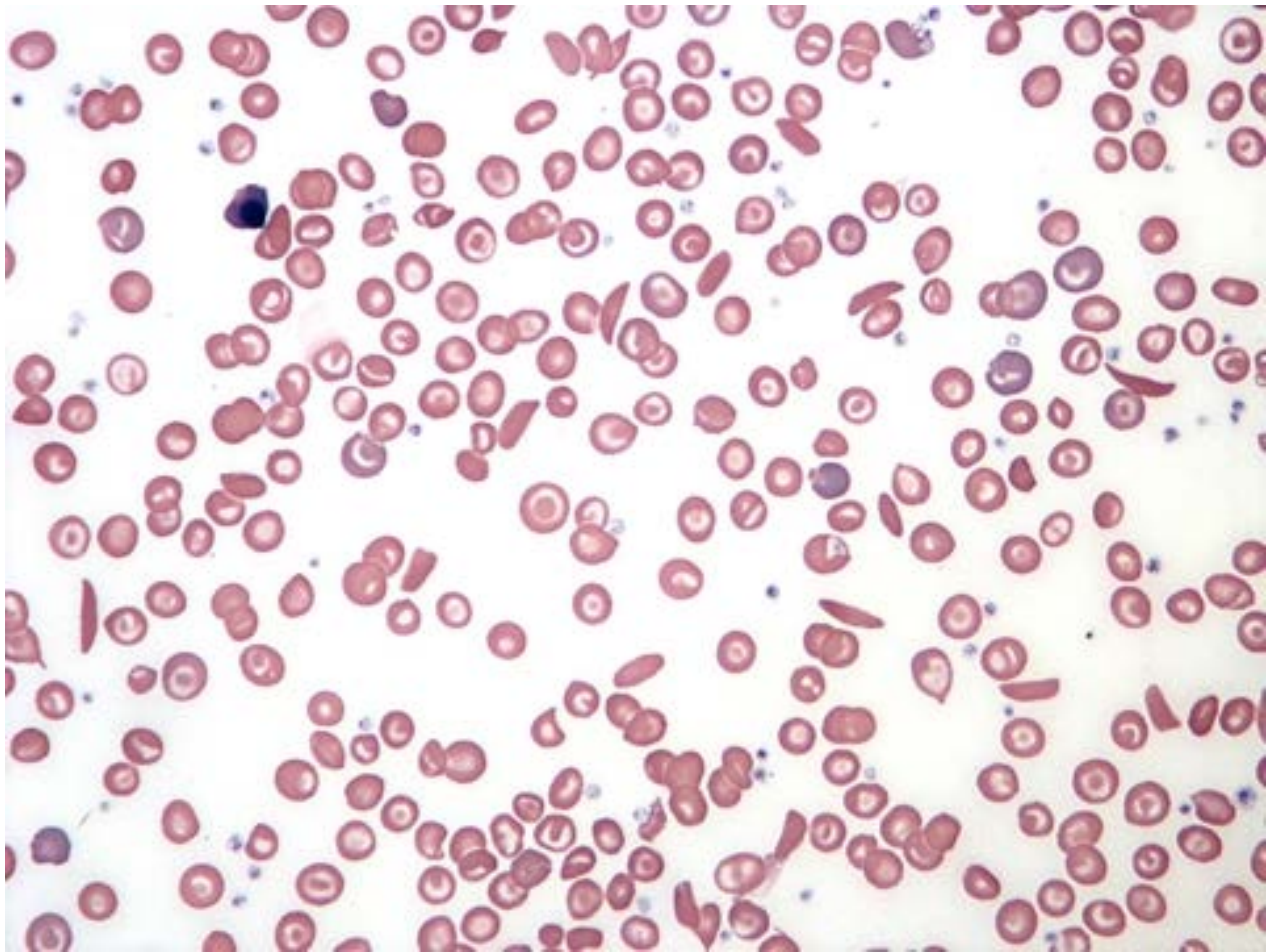


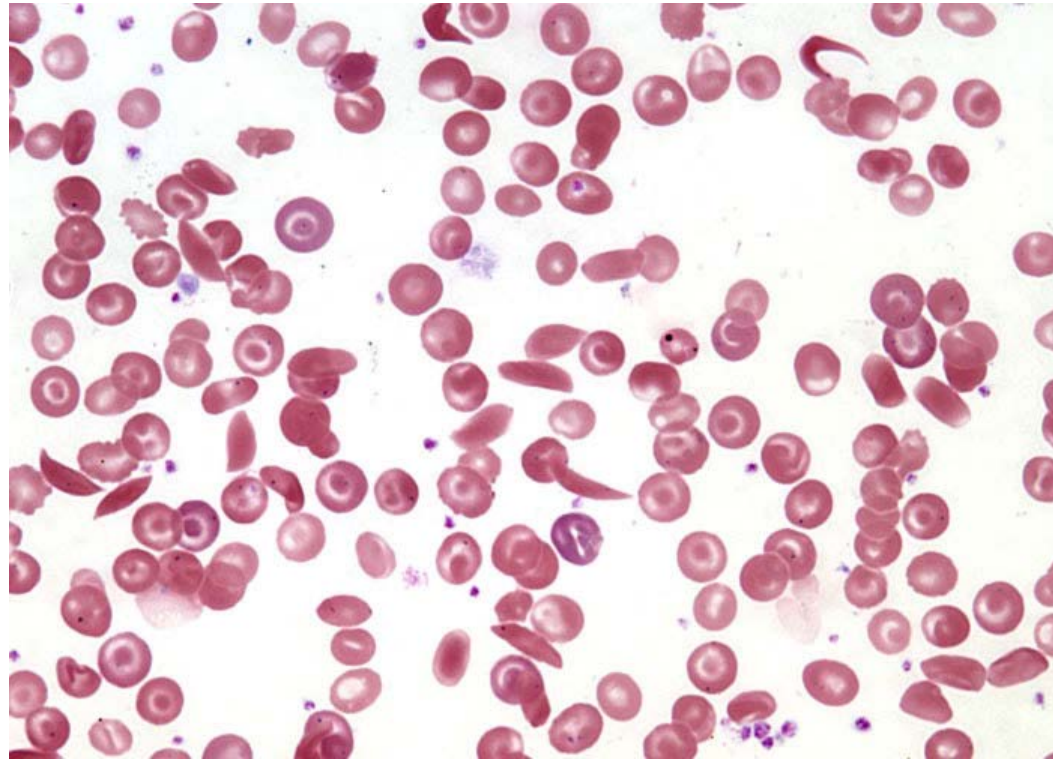


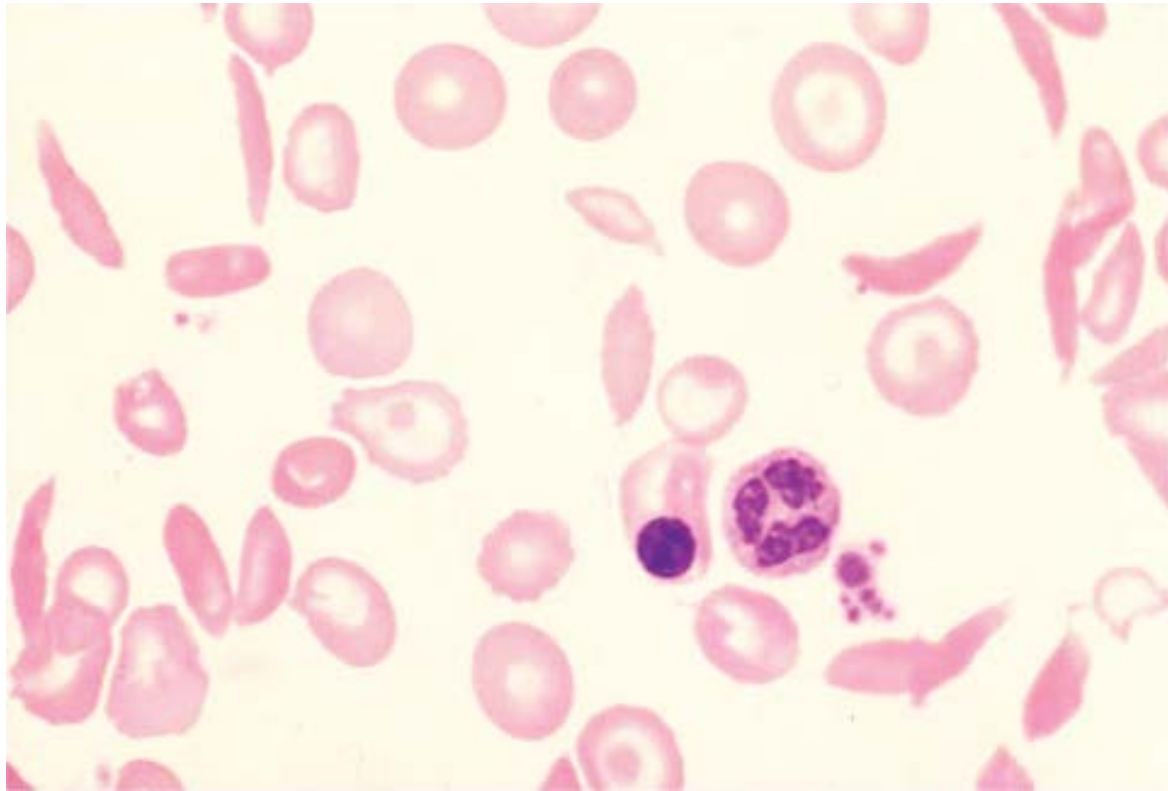


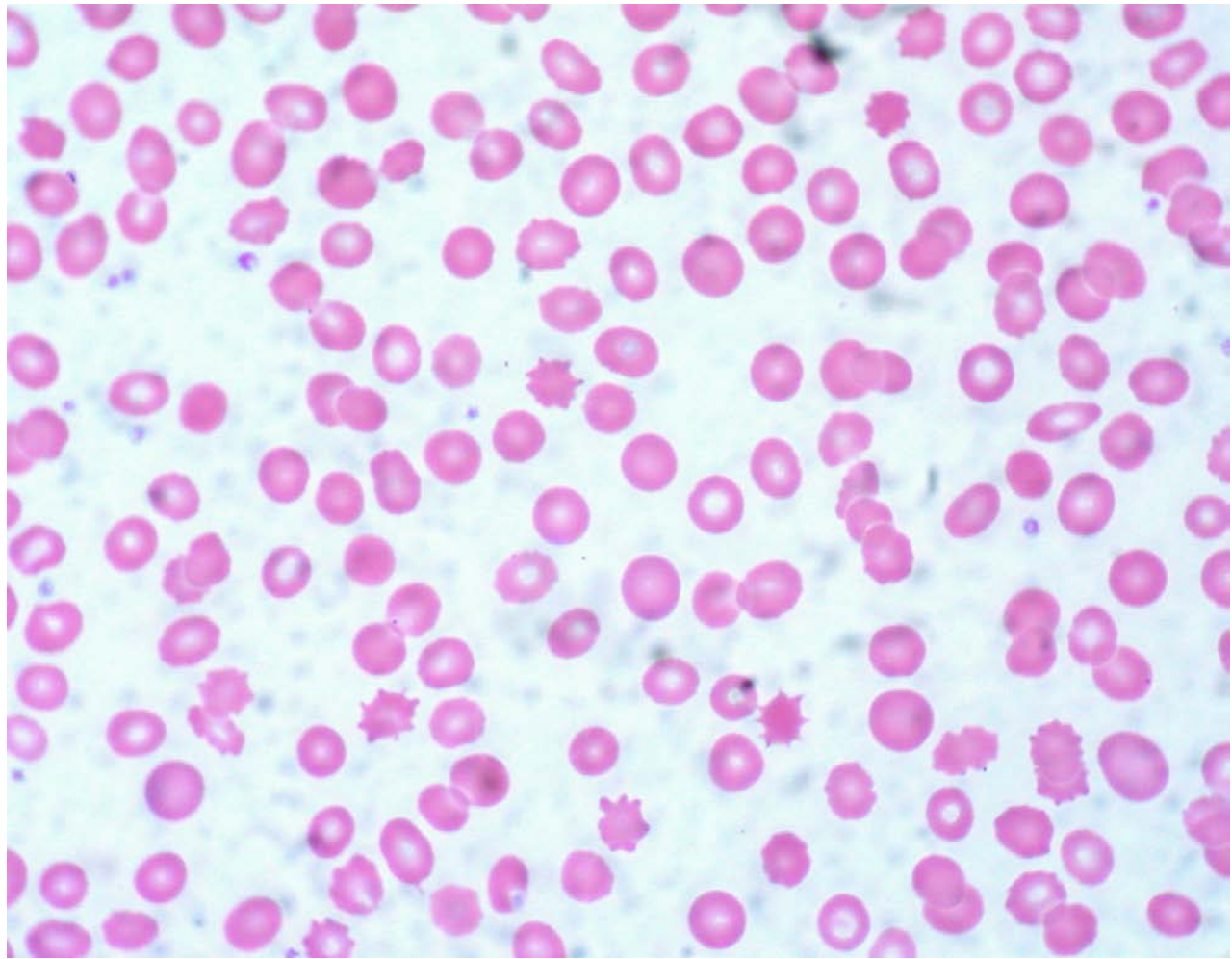
Atlas of Hematological Cytology. Masaryk University, Faculty of Medicine / University Hospital Brno. Available from: <http://www.leukemia-cell.org/atlas>

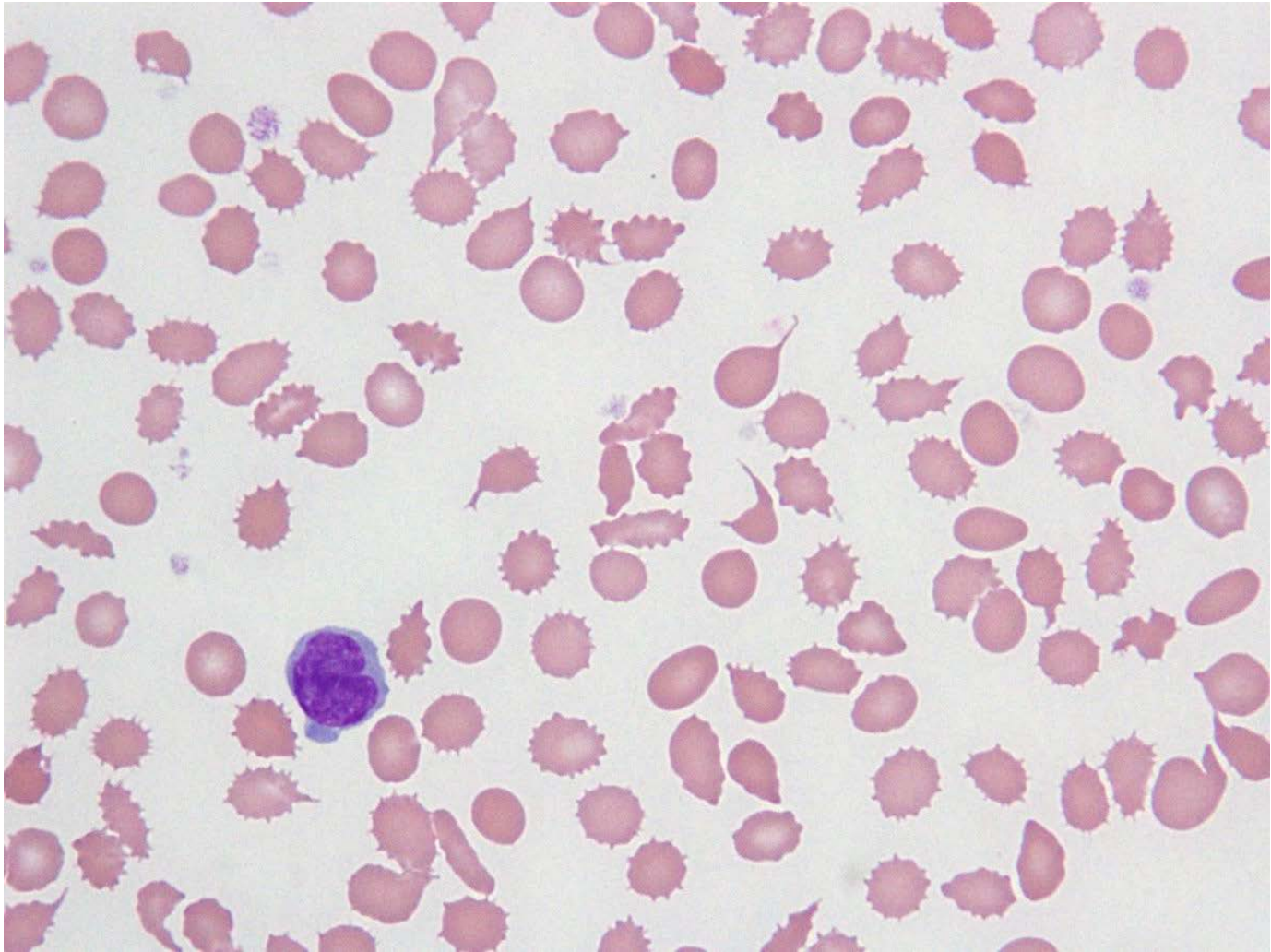


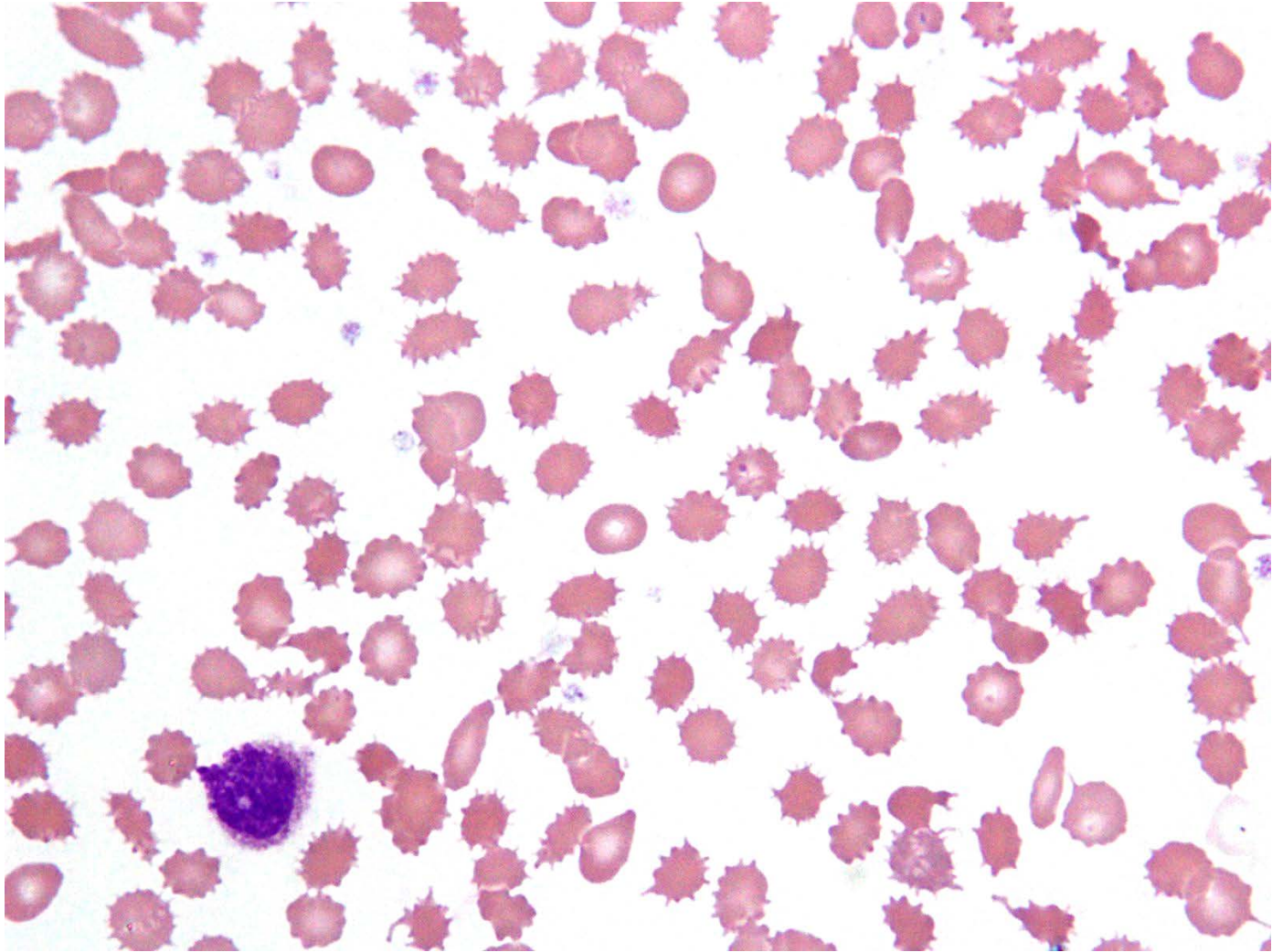


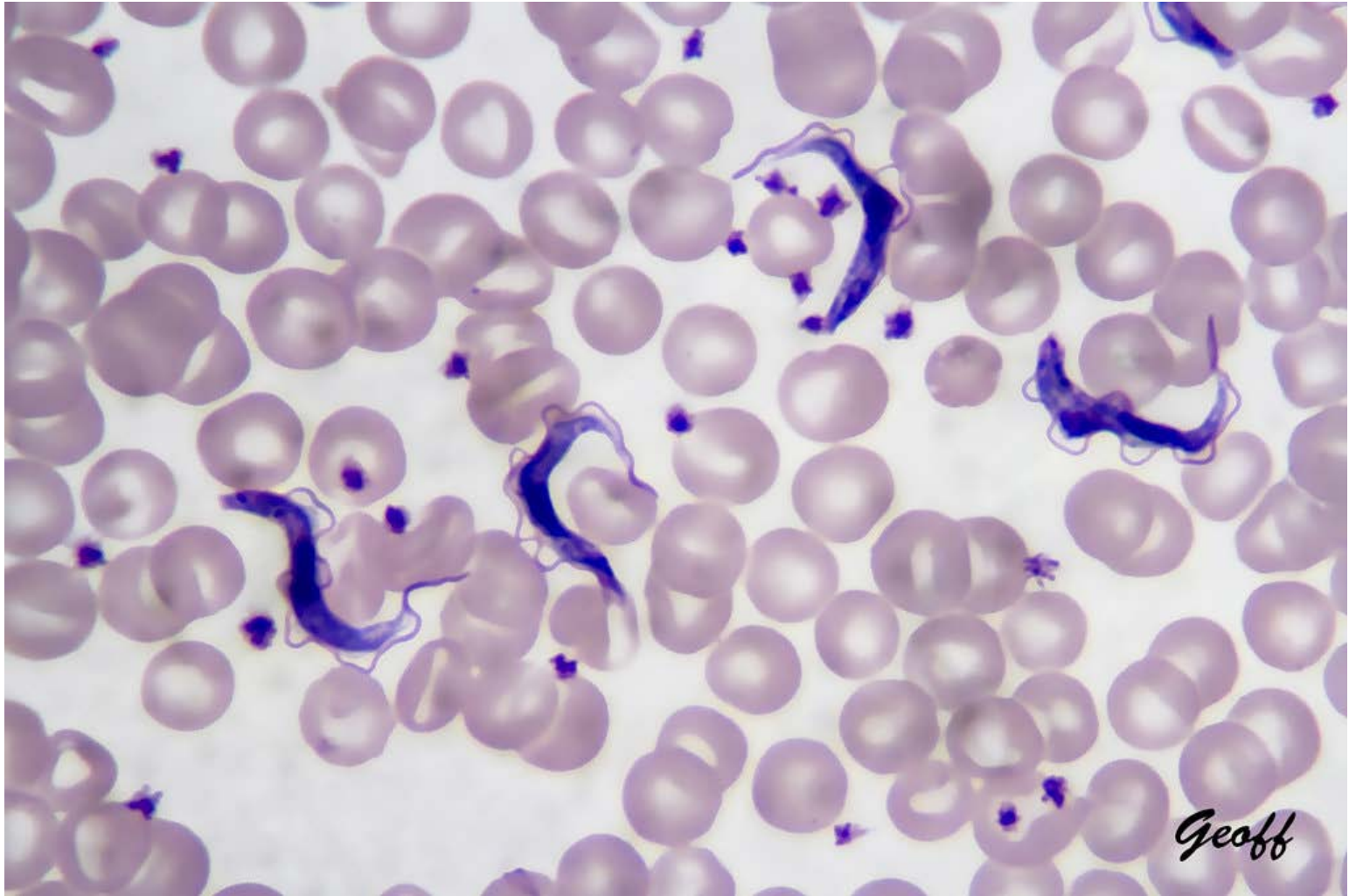


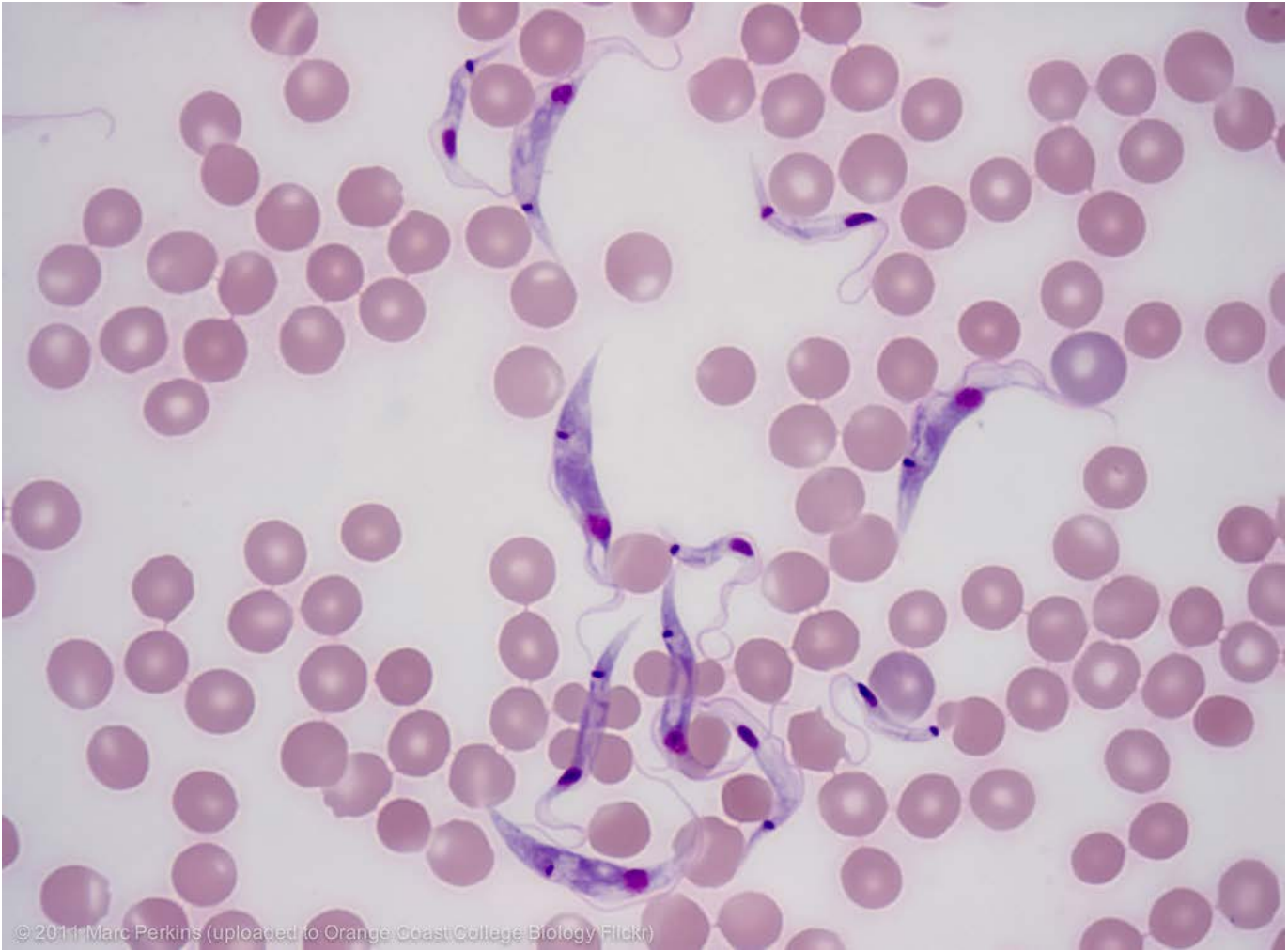




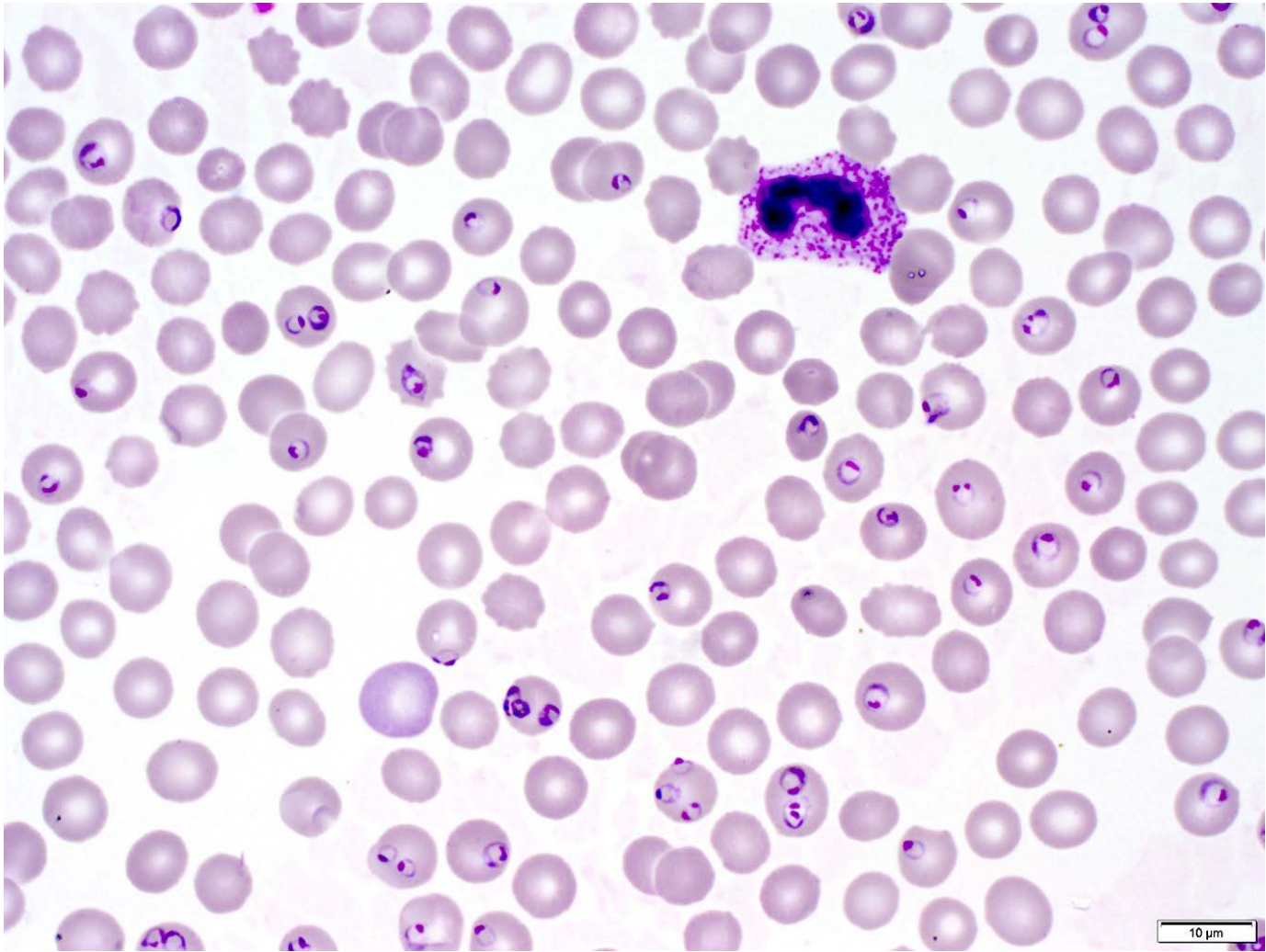


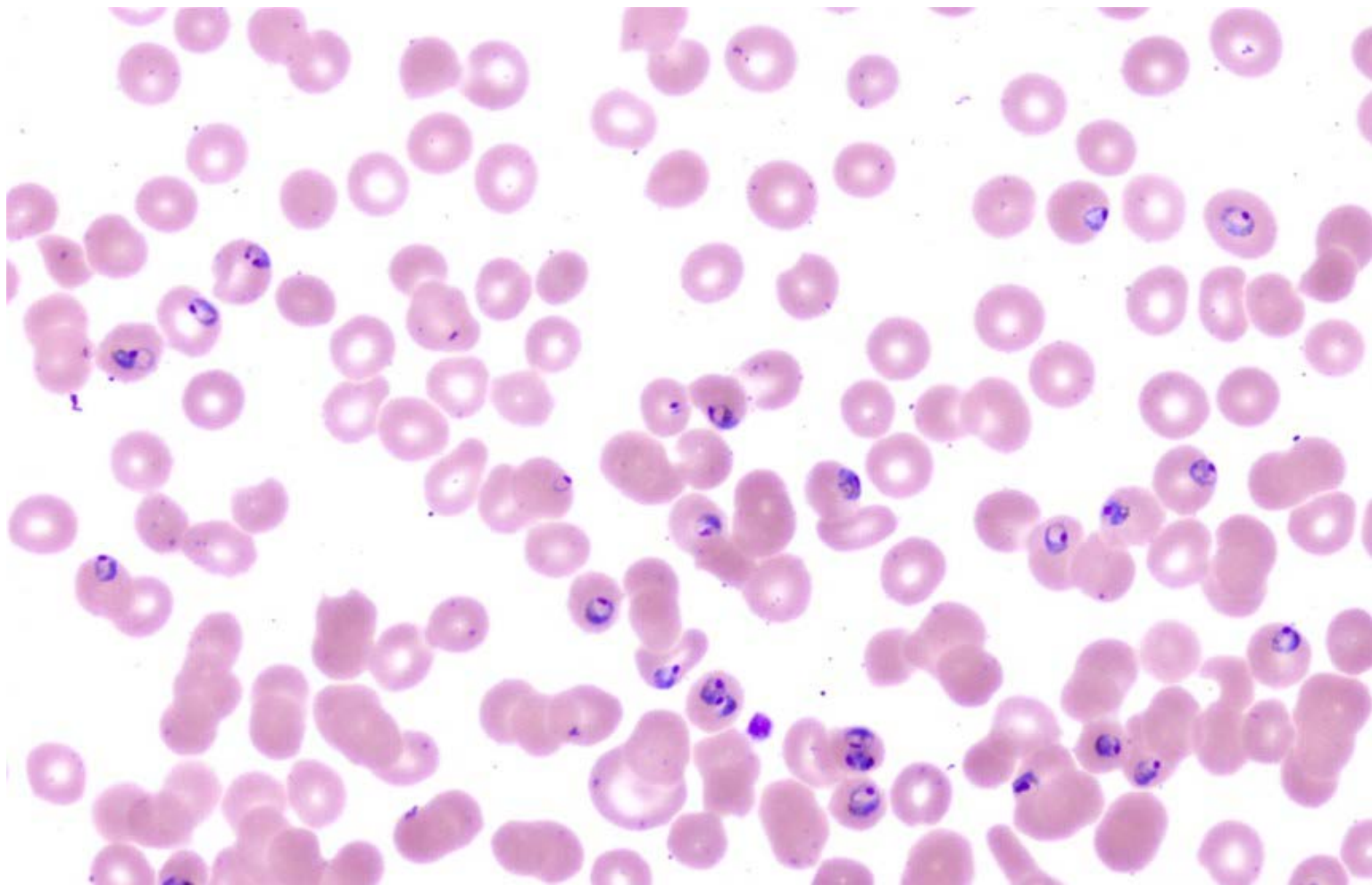






© 2011 Marc Perkins (uploaded to Orange Coast College Biology Flickr)





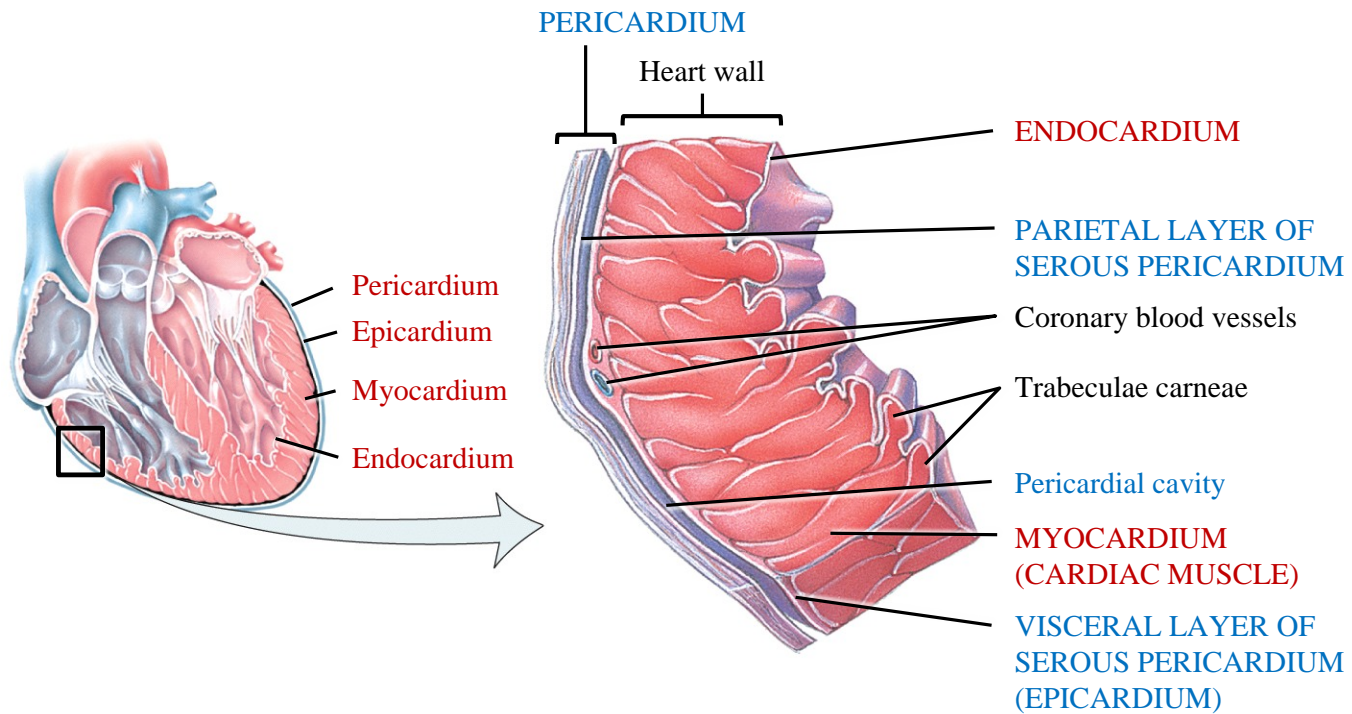
Heart Anatomy

Use the following pictures to help you identify terms from the lab term handout.

***You always only need to know the terms listed in the lab term handout!

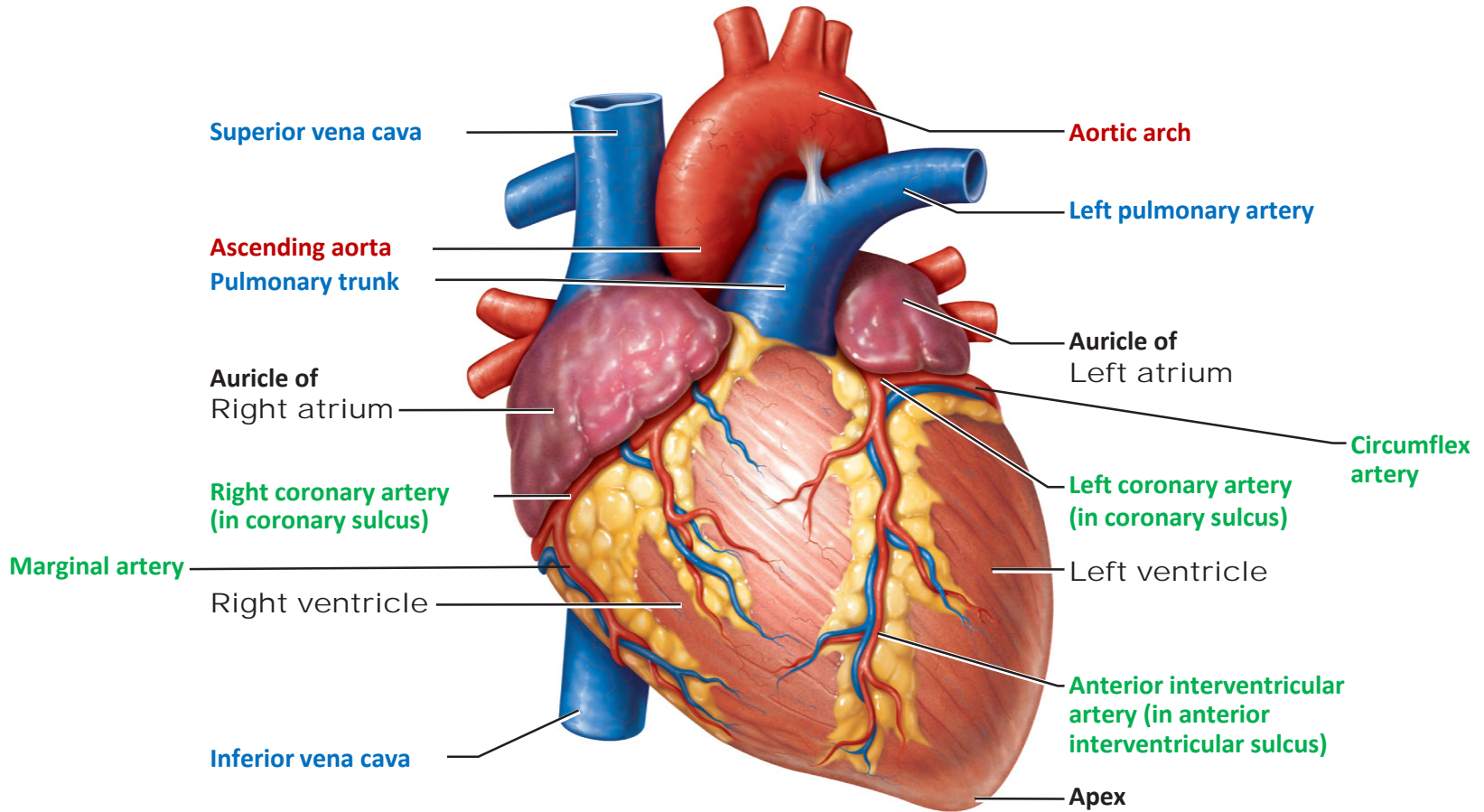
Another good resource is the Visible Body ATLAS app: <http://atlas.visiblebody.com>

Don't forget that to use the link to download the atlas to a personal device, the device must first be connected to the MCPA Wi-Fi at the Rockville campus.



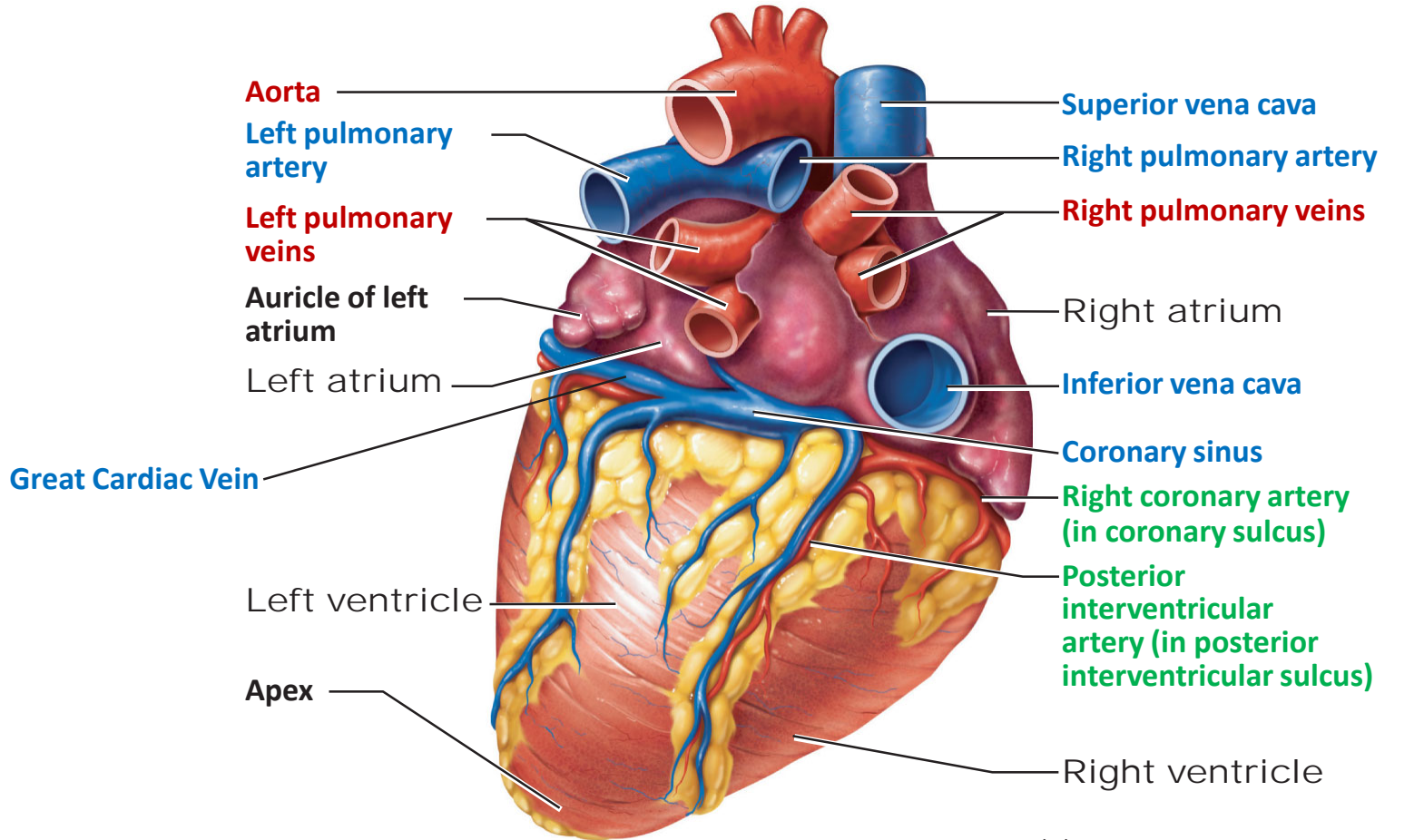
(a) Portion of pericardium and right ventricular heart wall showing divisions of pericardium and layers of heart wall

Figure 18.4b Gross anatomy of the heart.



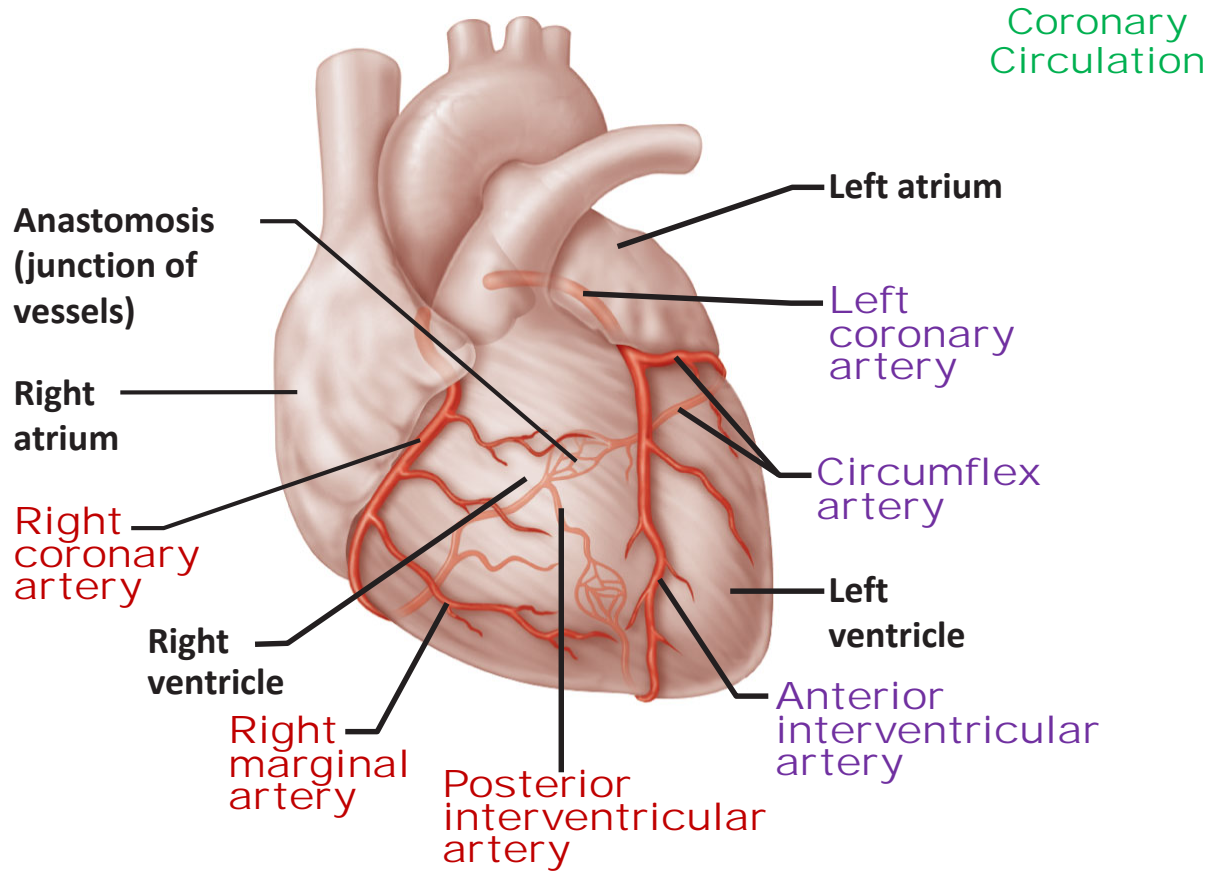
(b) Anterior view

Figure 18.4d Gross anatomy of the heart.



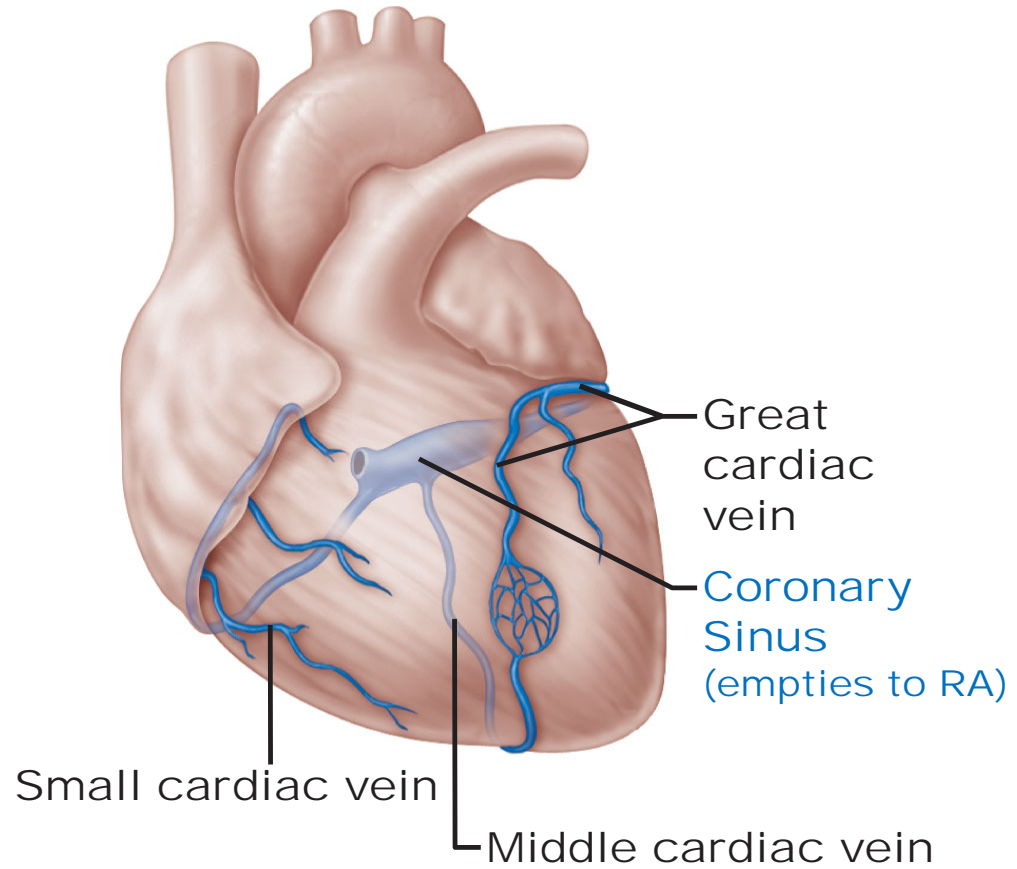
(d) Posterior surface view

Figure 18.7a Coronary circulation.

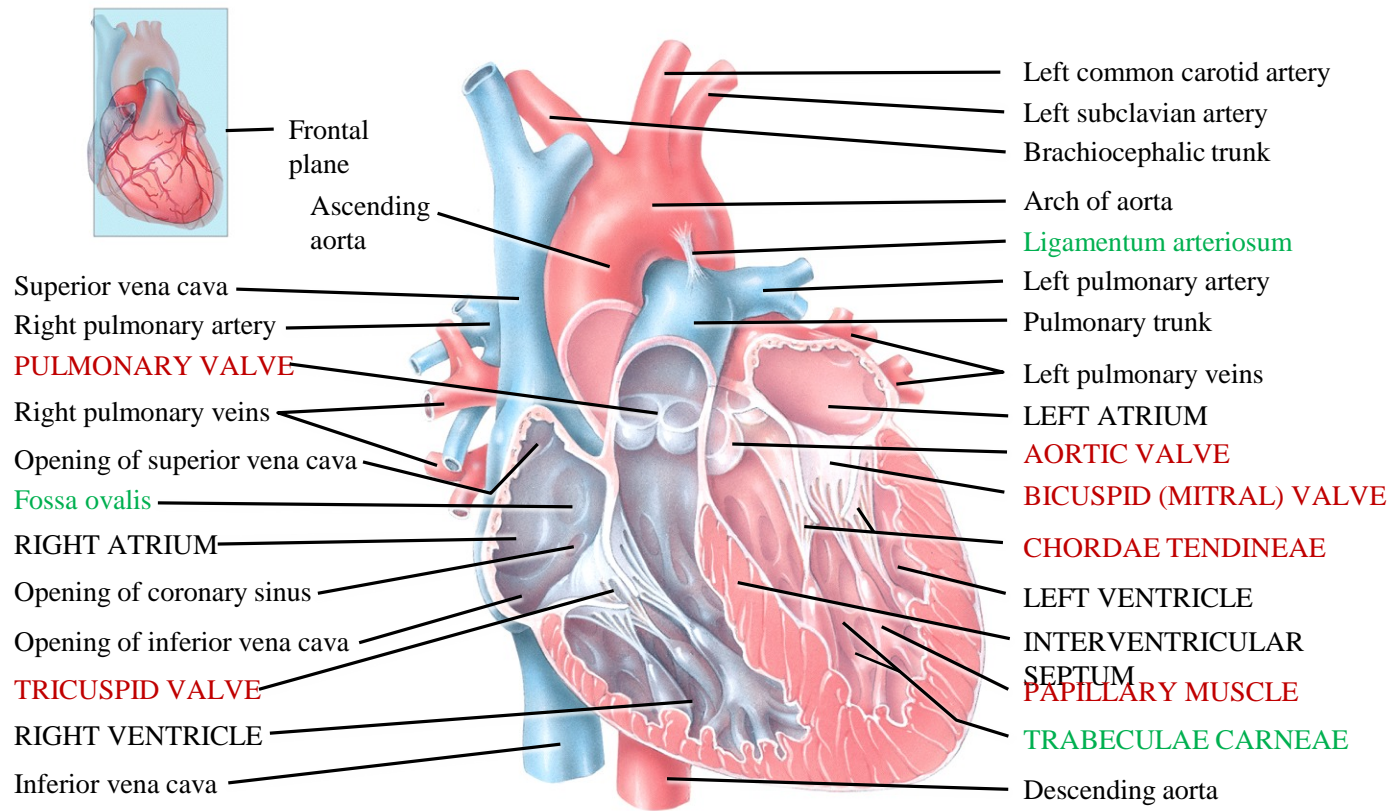


(a) The major coronary arteries

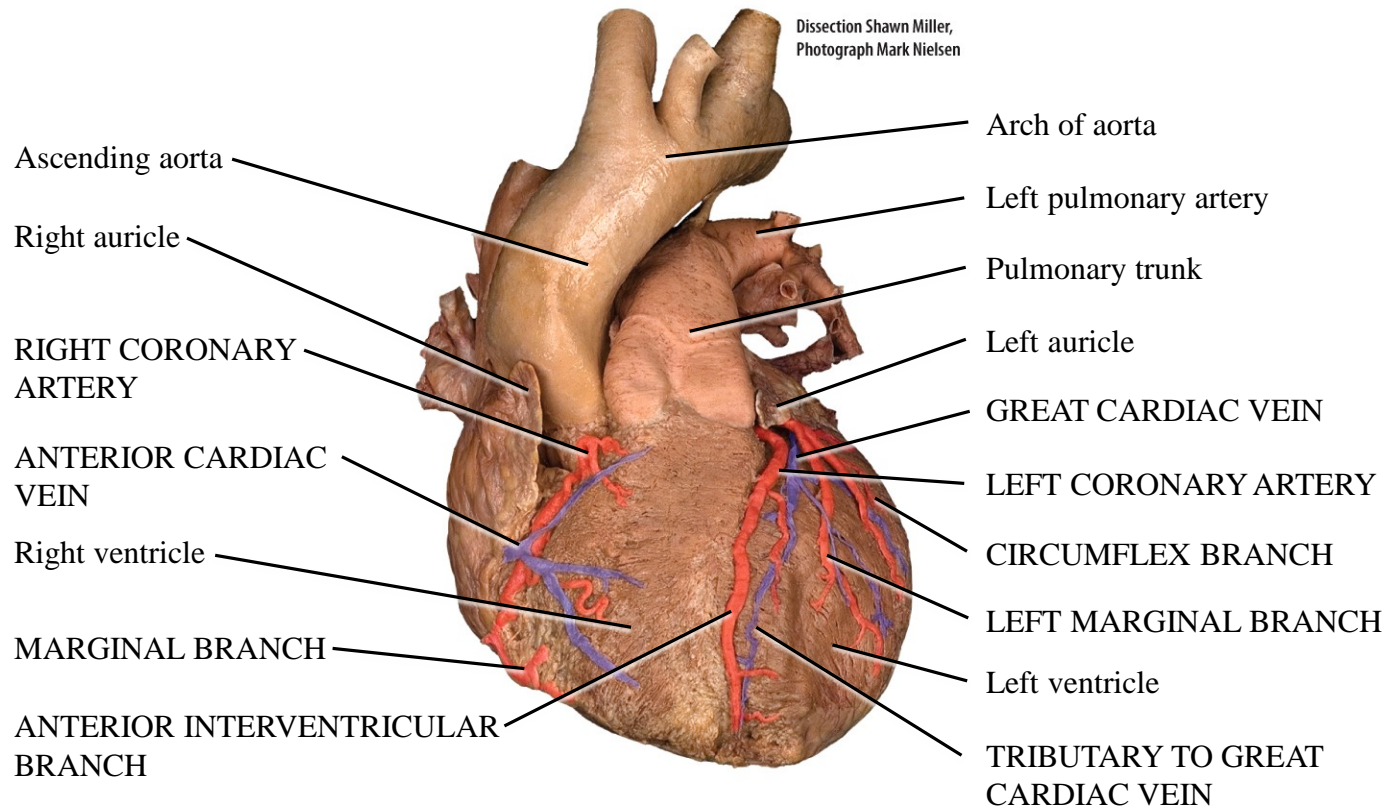
Figure 18.7b Coronary circulation.



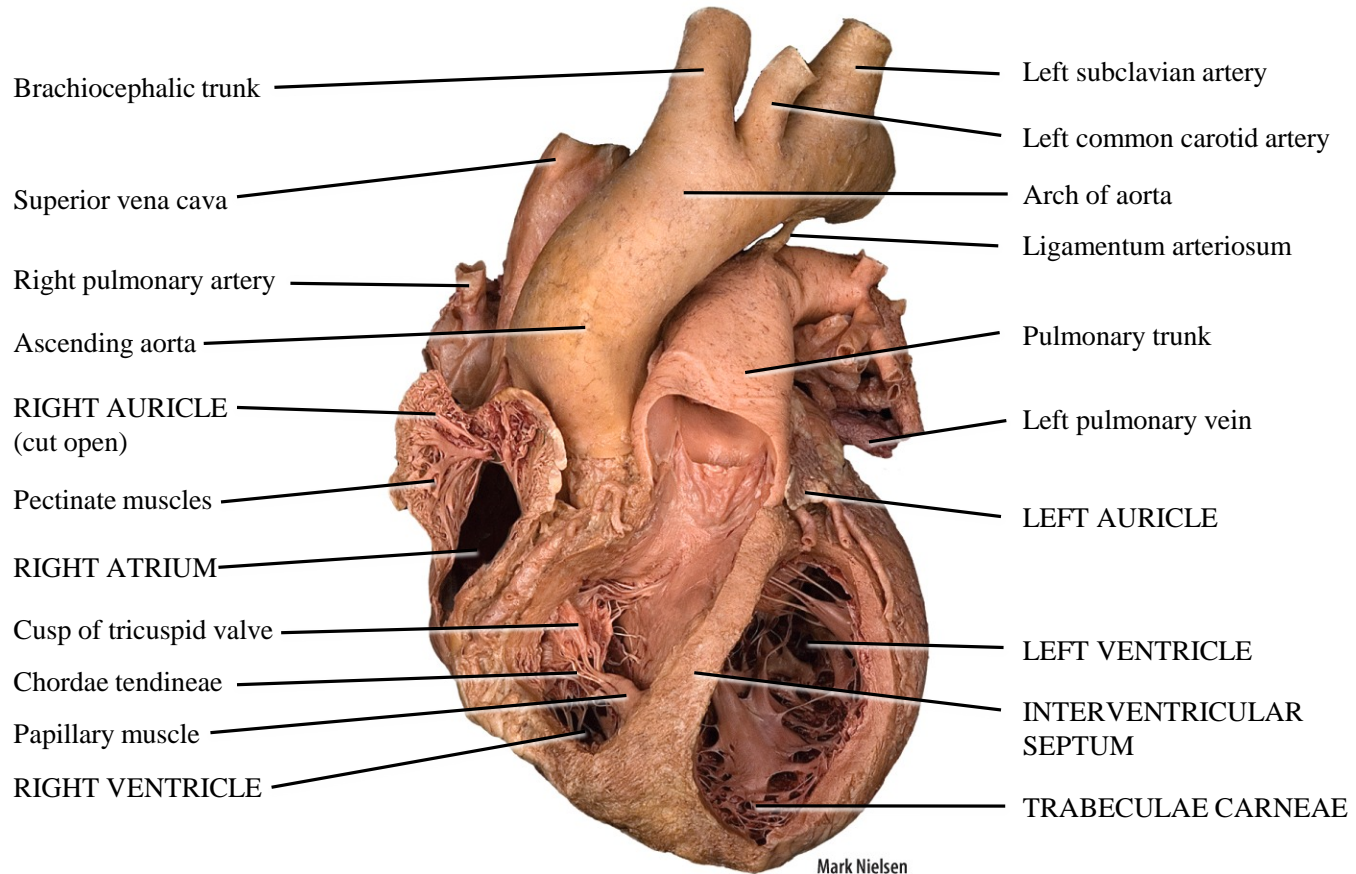
(b) The major cardiac veins



(a) Anterior view of frontal section showing internal anatomy

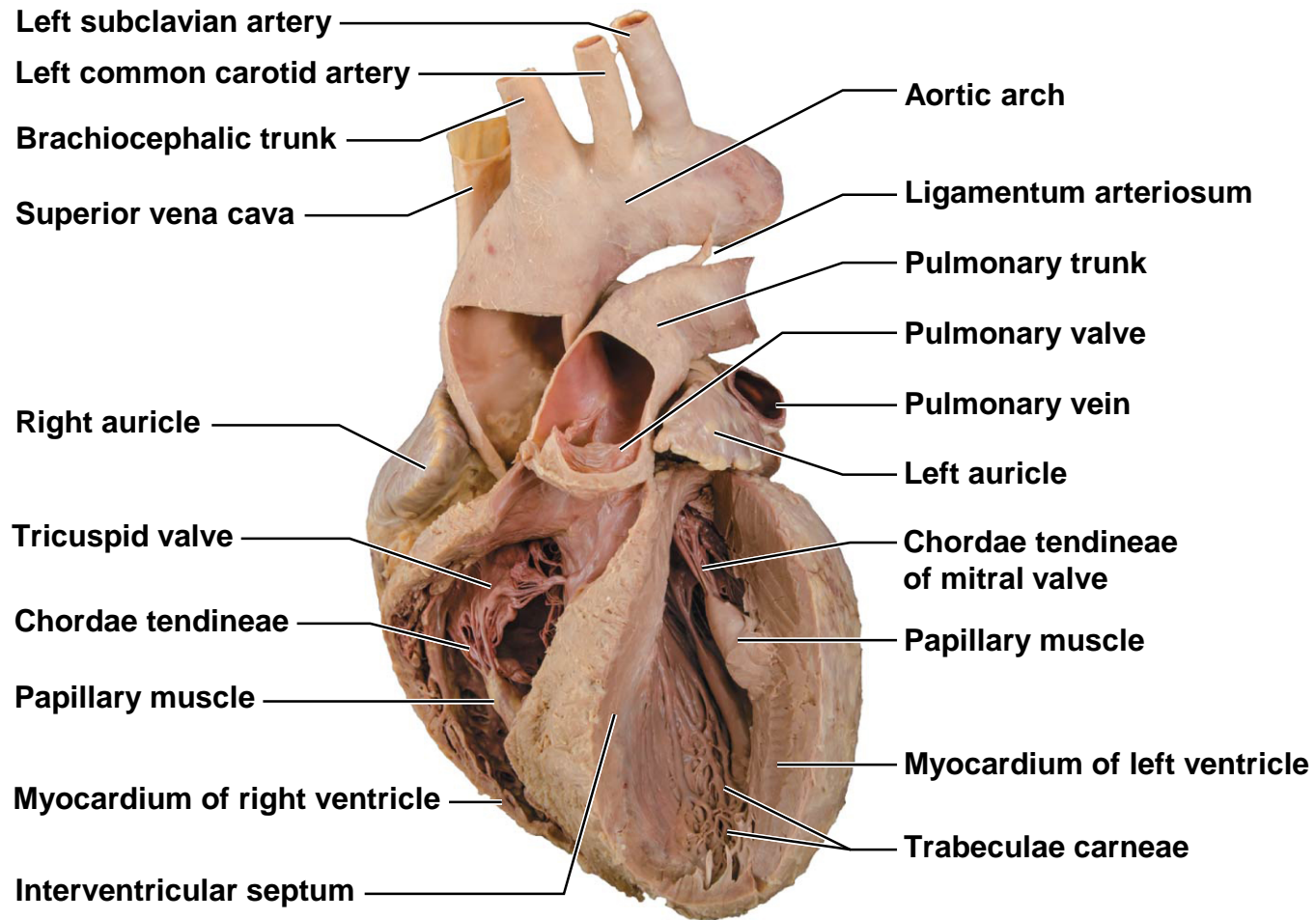


(c) Anterior view



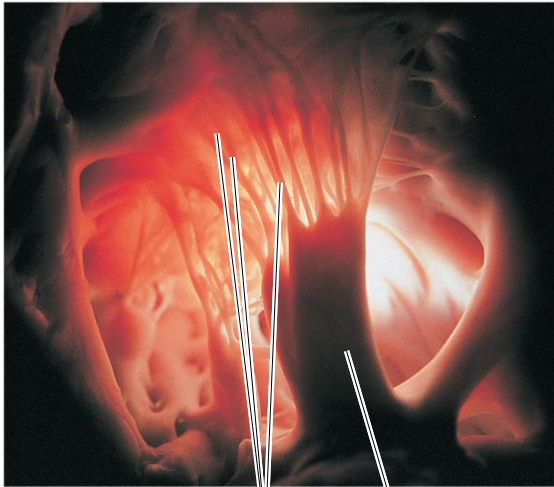
(b) Anterior view of partially sectioned heart

Figure 18.5f Gross anatomy of the heart.



(f) Internal aspect of ventricles; dissection of view similar to (e)

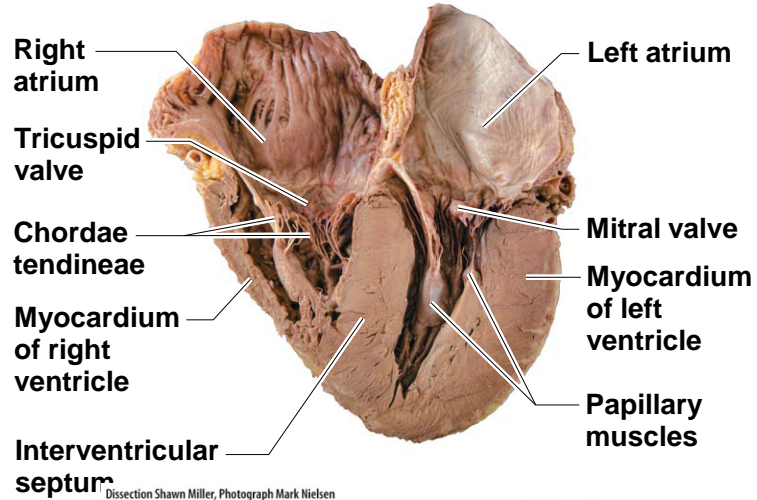
Figure 18.6-2 Heart valves (continued).



Chordae tendineae attached to tricuspid valve flap

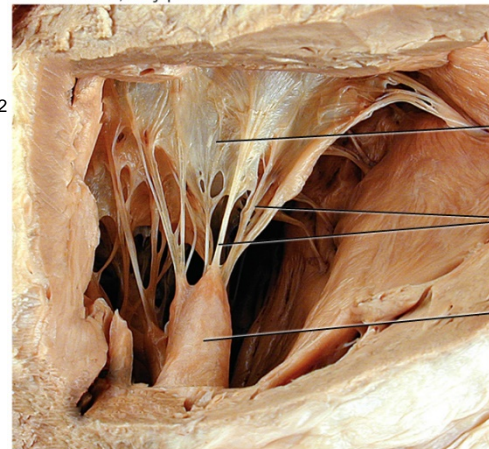
Papillary muscle

(c) © 2016 Pearson Education, Inc.



Dissection Shawn Miller, Photograph Mark Nielsen

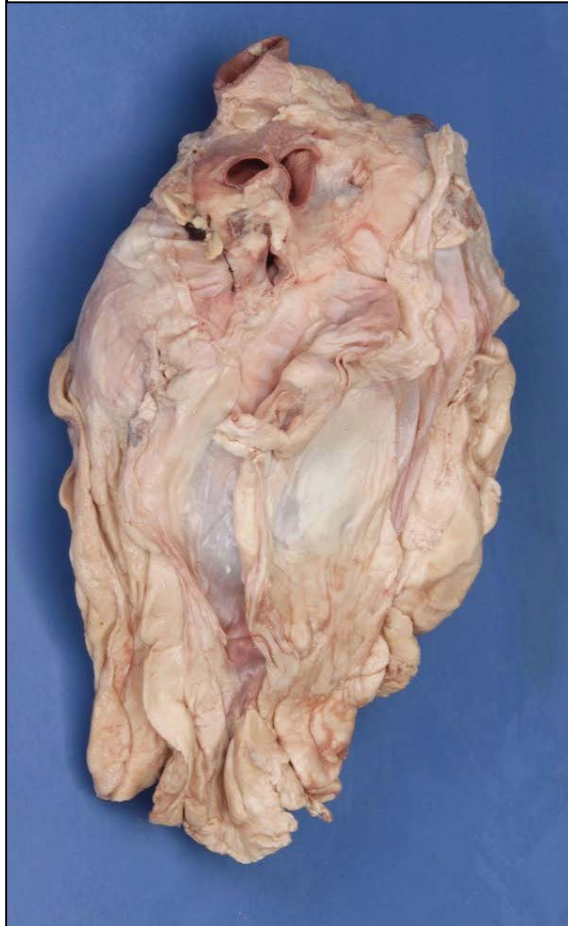(d) © 2



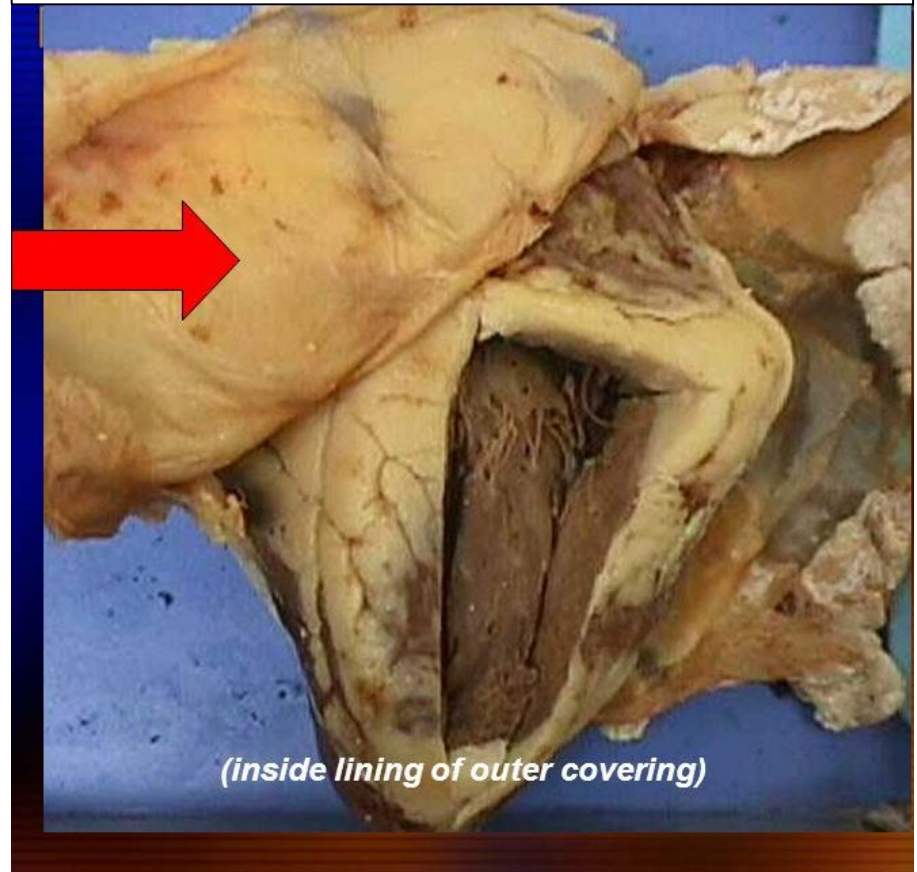
(c) Tricuspid valve open

Copyright © 2014 John Wiley & Sons, Inc. All rights reserved.

Before Cut
(Parietal Layer Intact)

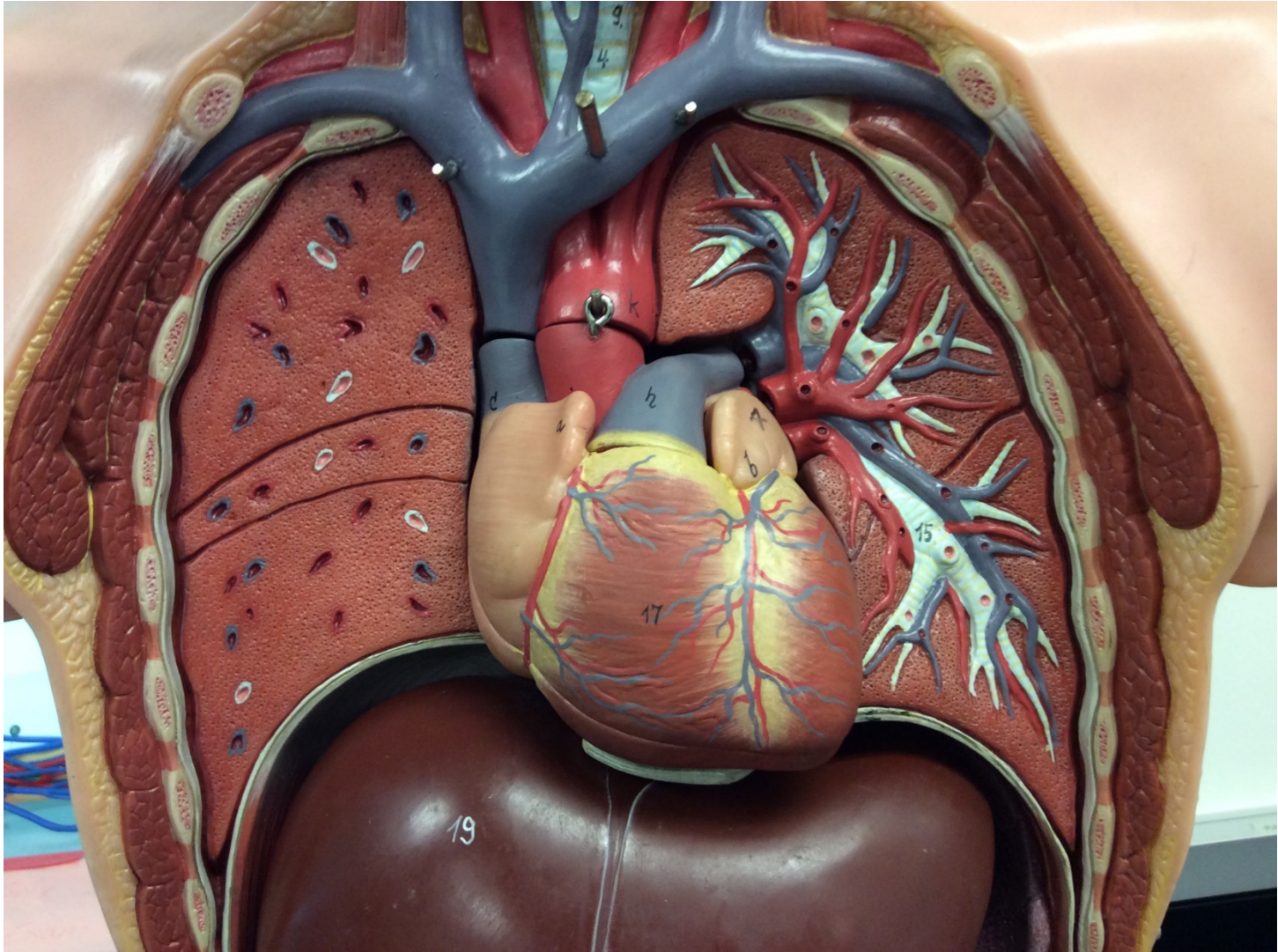


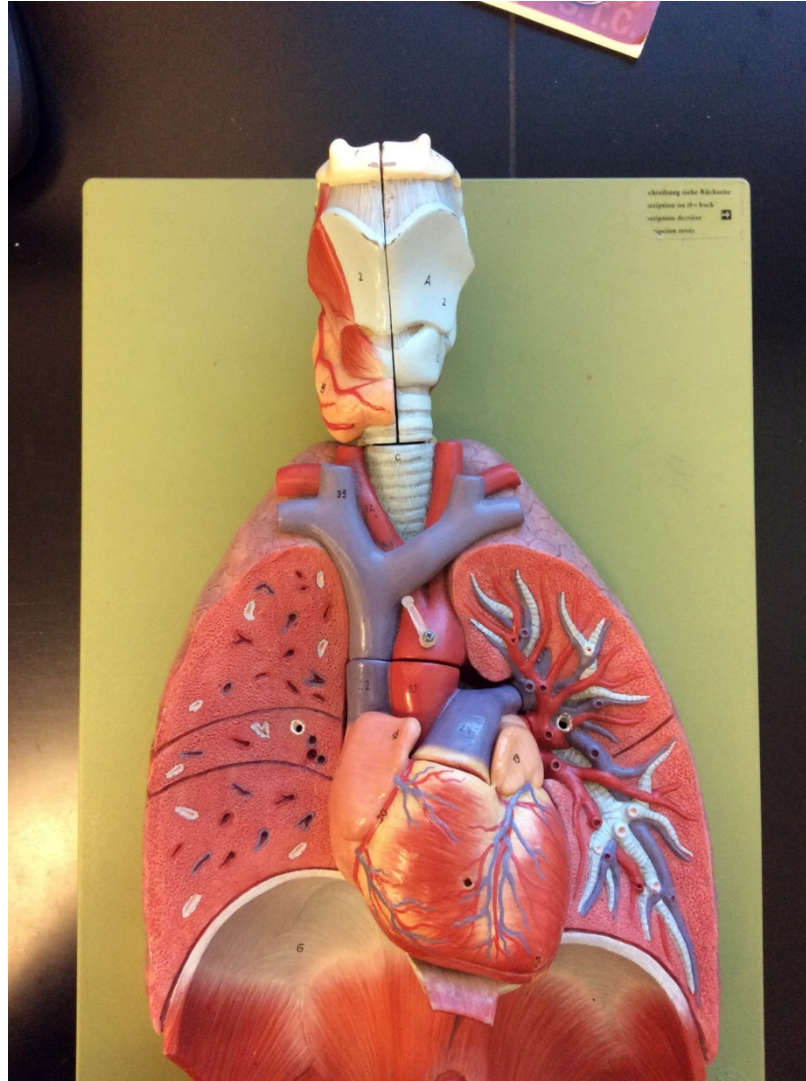
After Cut
(Inside of Parietal Layer at arrow tip)

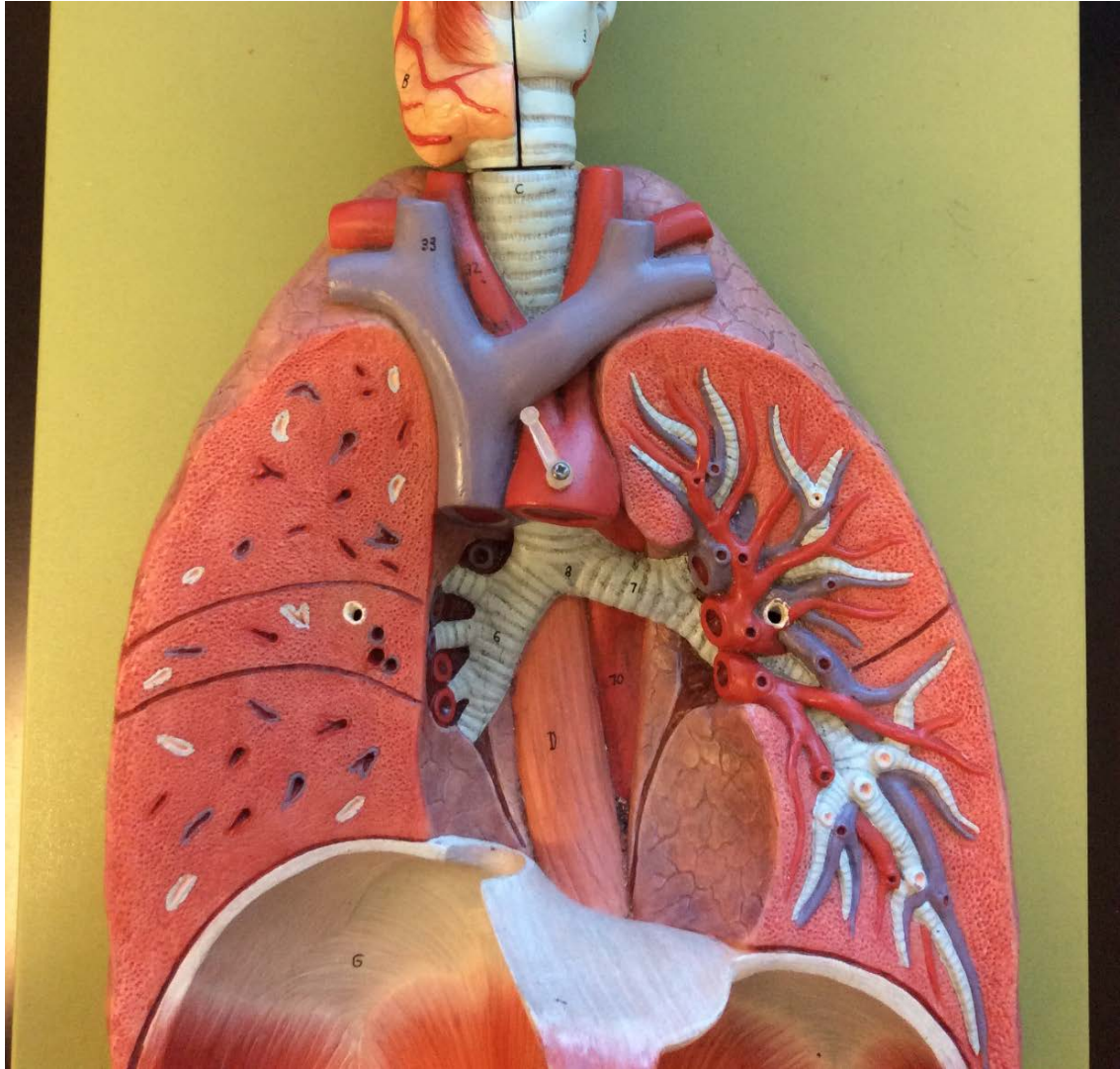


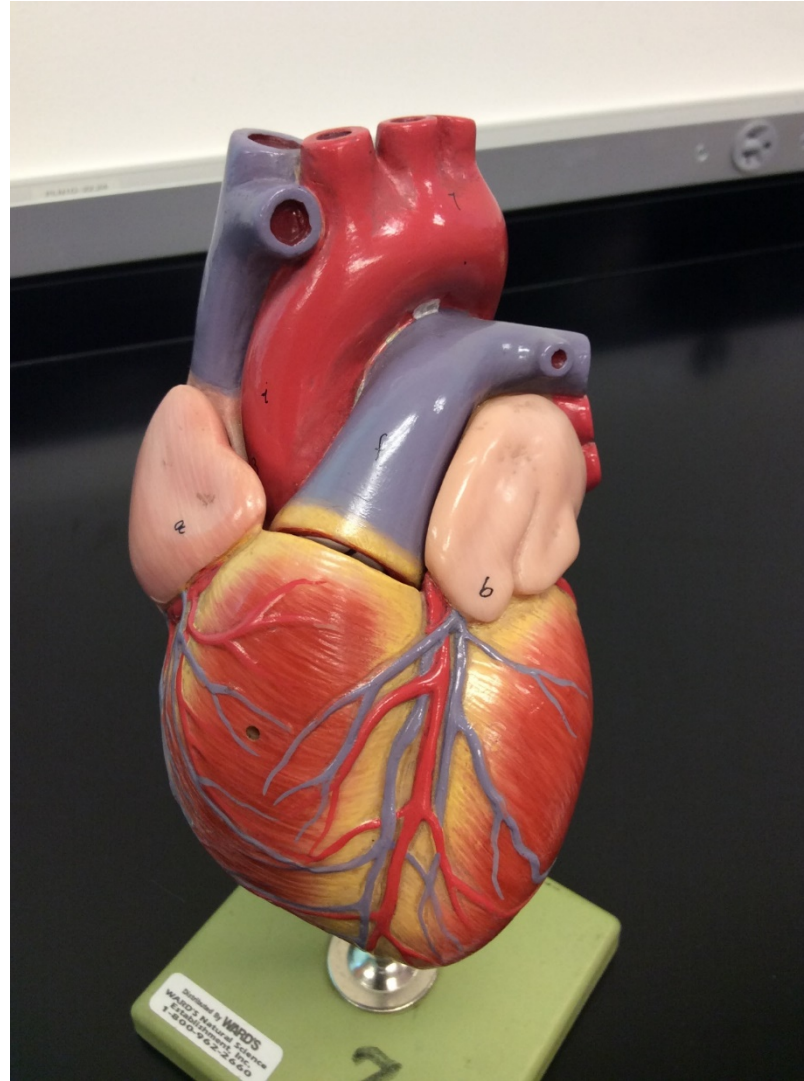
Use the following pictures to help you practice finding the terms from the lab term handout on unlabeled images.

- Remember, you won't learn them if you don't take plenty of time to practice on pictures with NO labels (including no labels for what type of slide it is on histology pictures)!
- Also, be sure to mix up the order once you get comfortable with the unlabeled slides.
- Over the weekend, once you are feeling confident with the pictures here, do the histology quizzes in PAL (from the Pearson website) to get practice with new pictures that you haven't seen.

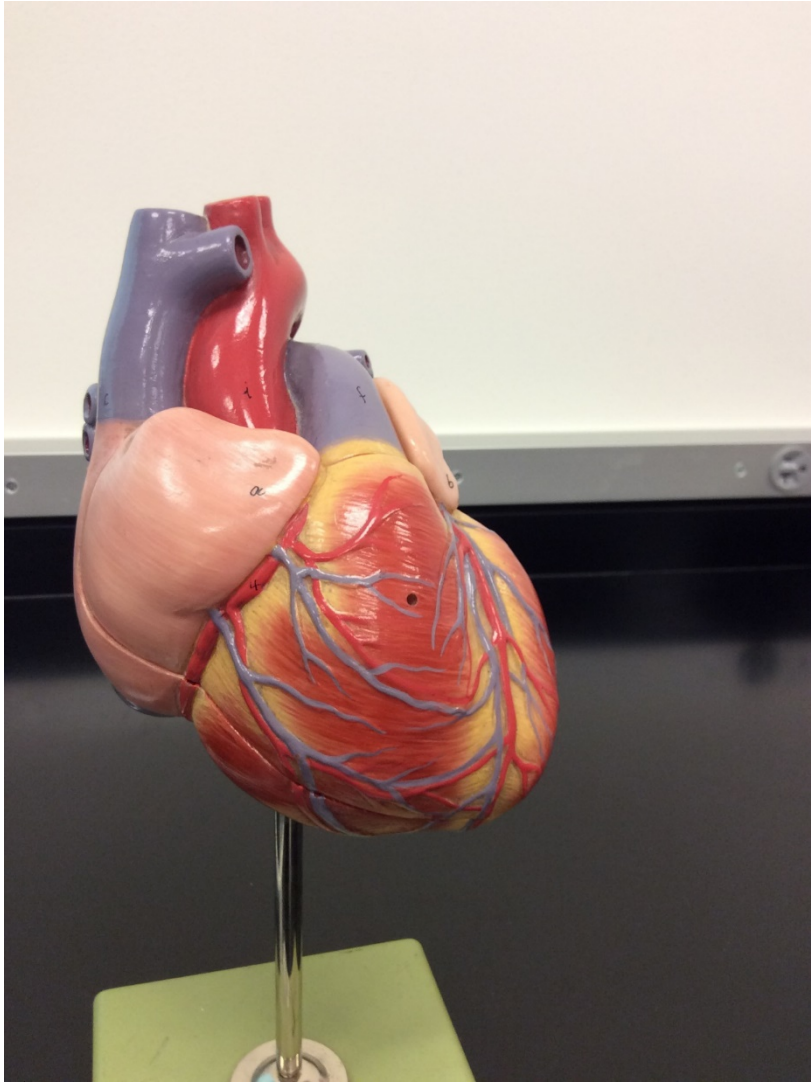


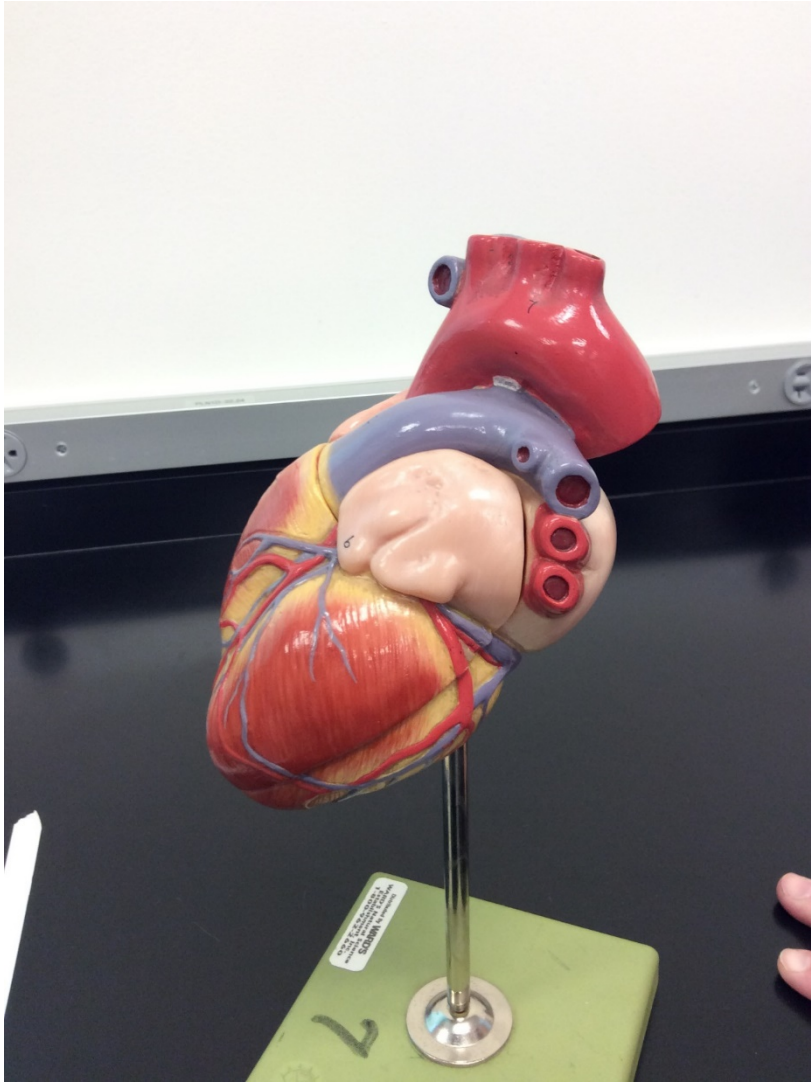


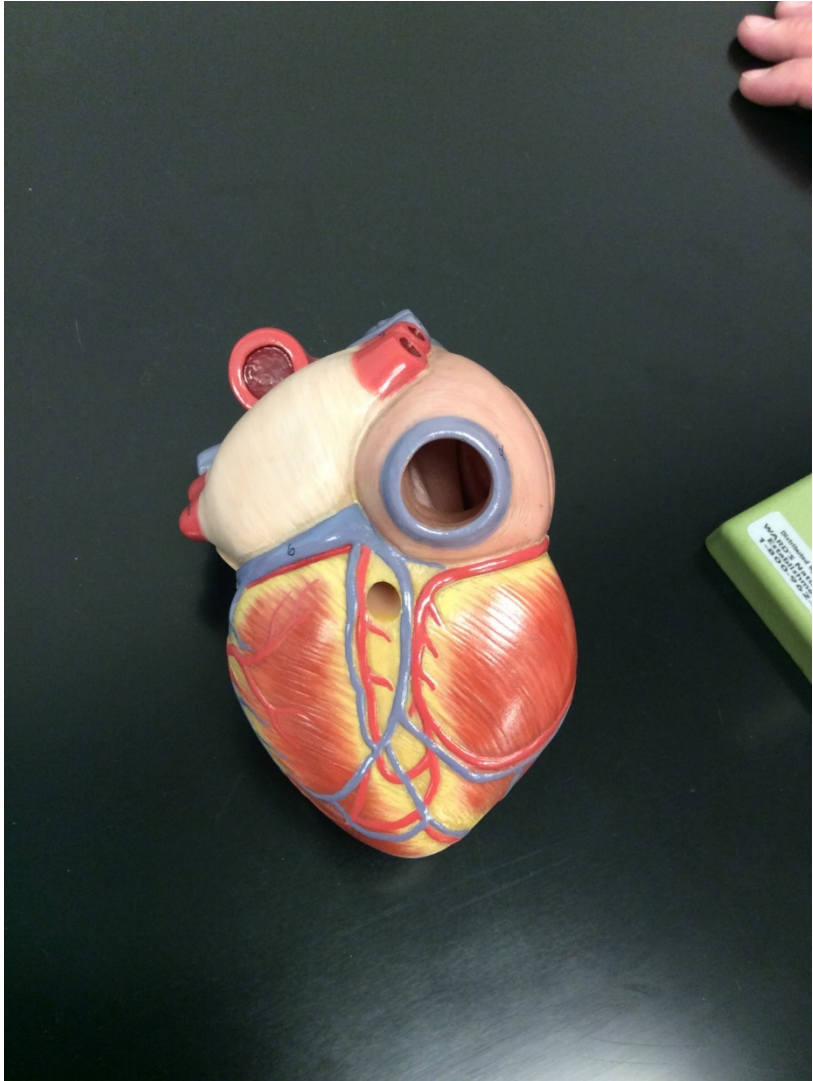

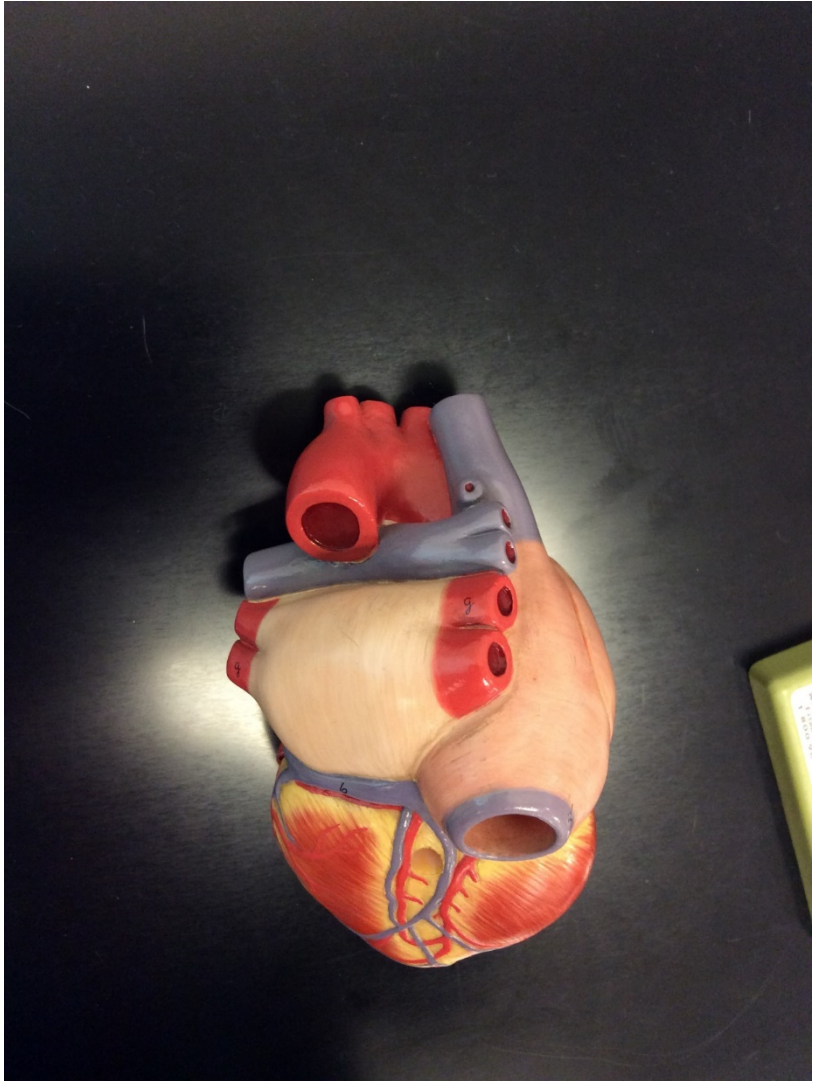


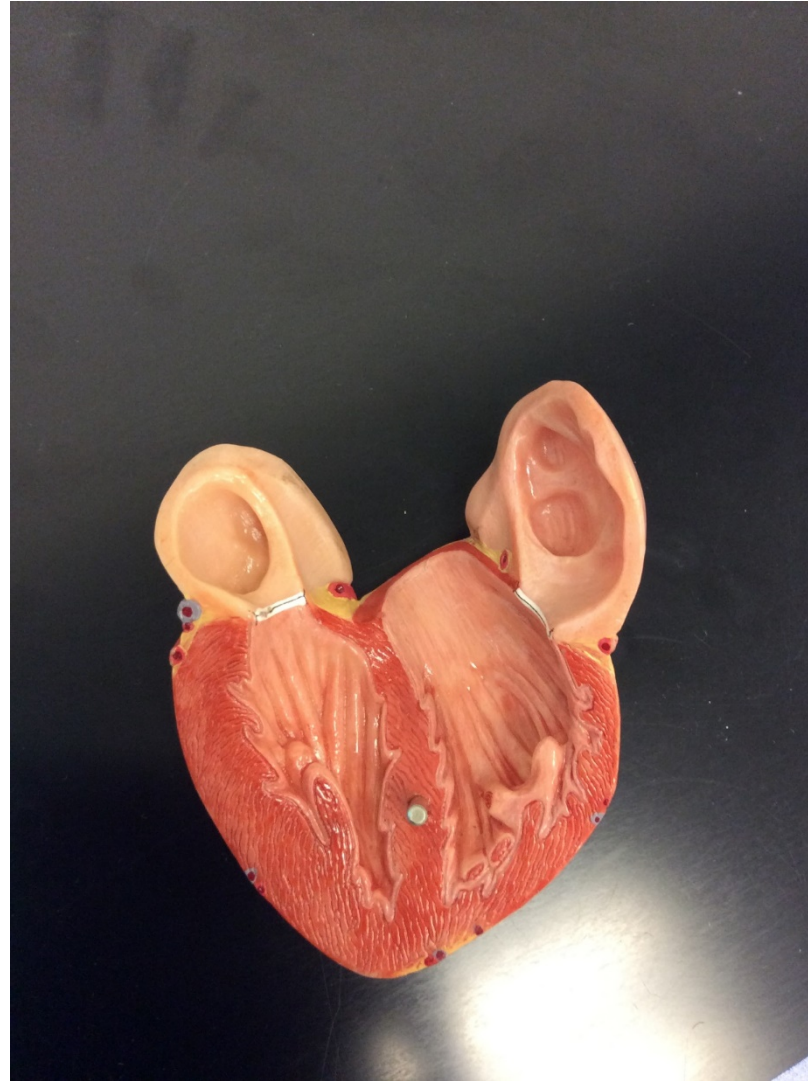
**Human Sized Heart
(Intact)**



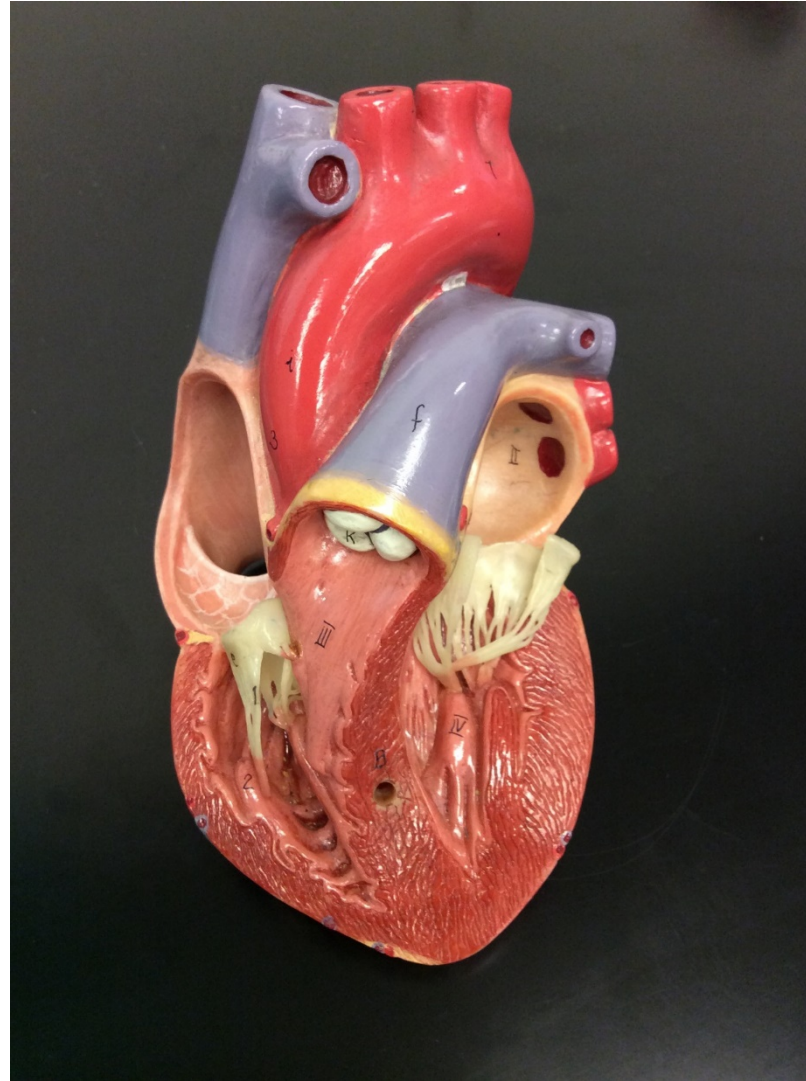



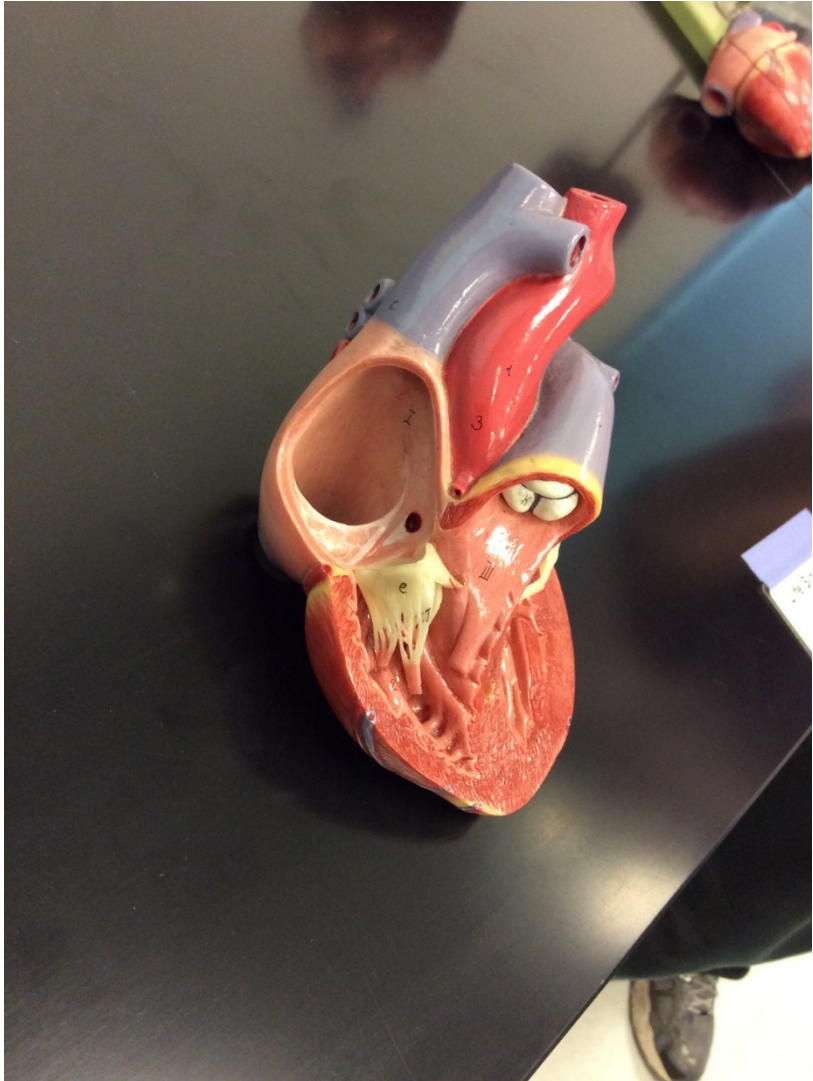


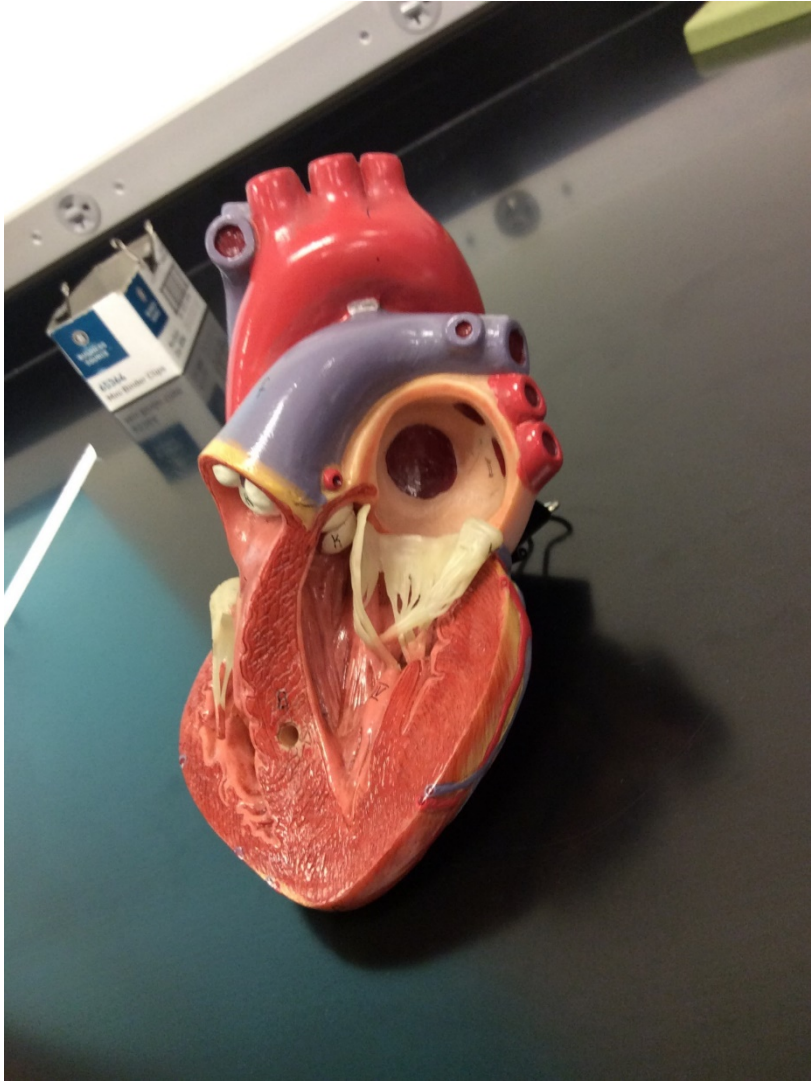


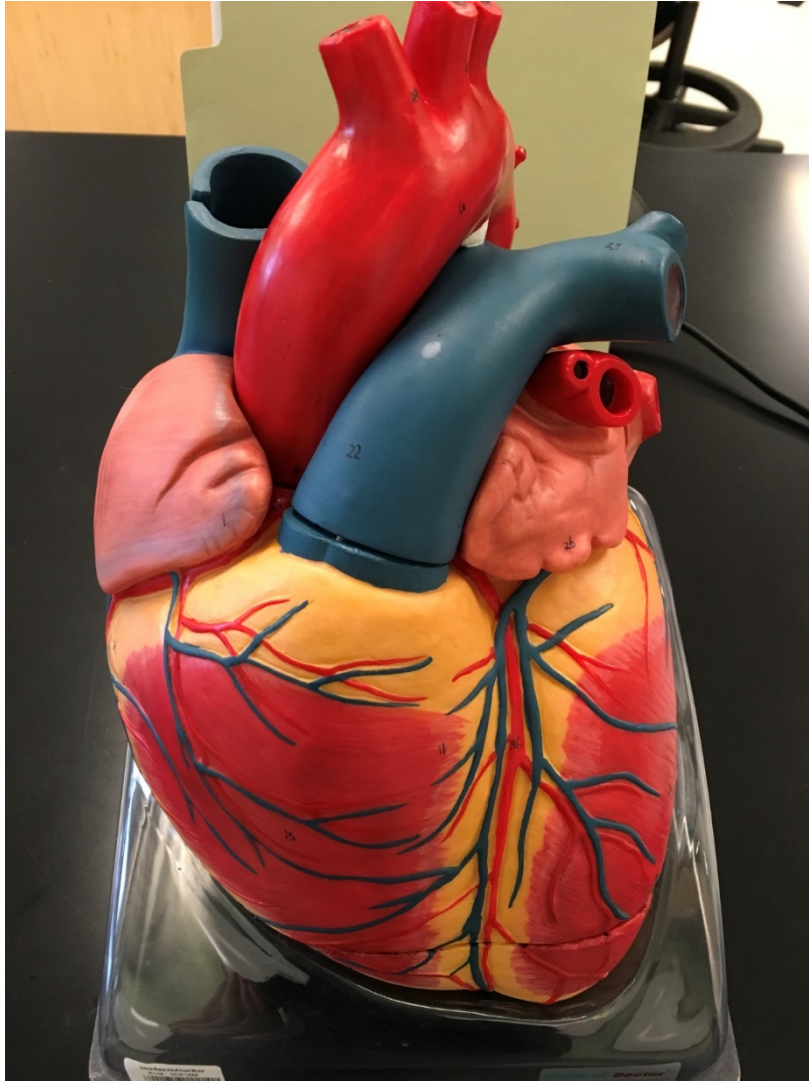
**Human Sized Heart
(Pulled off the front
and looking into it)**



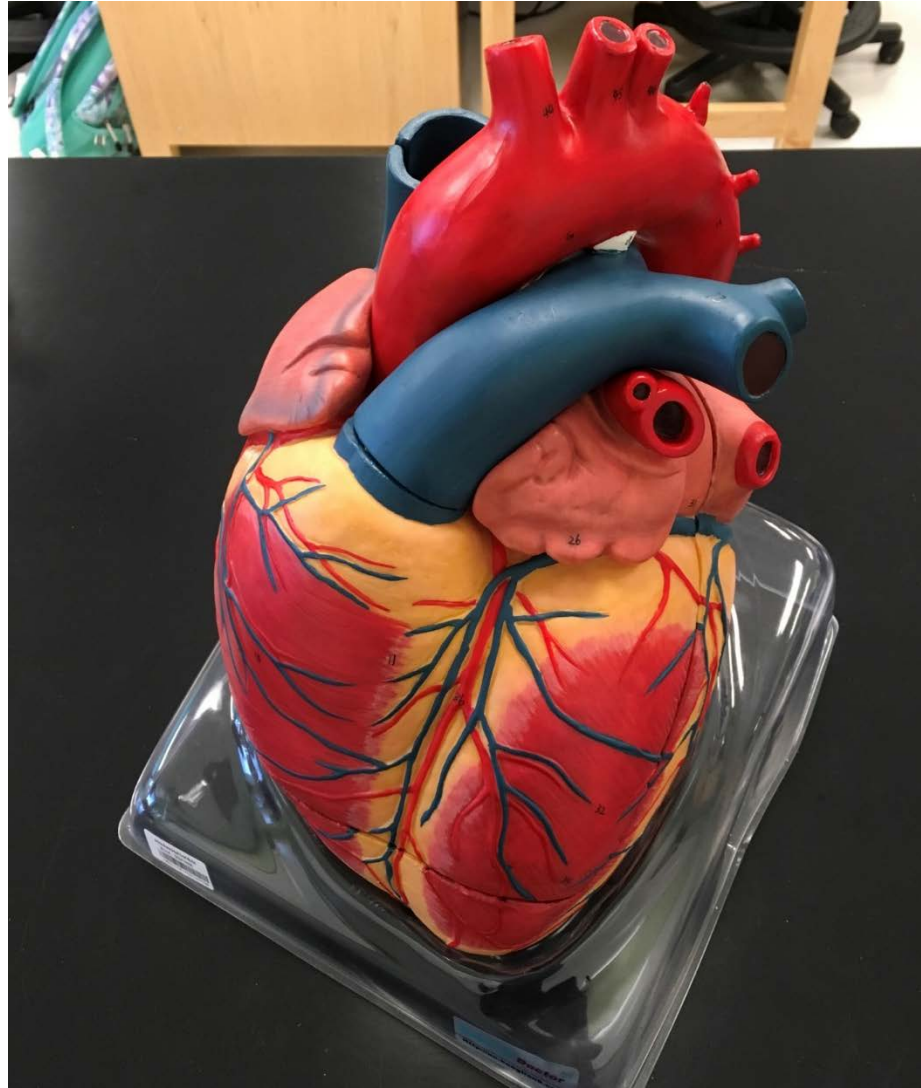**Human Sized Heart
(Pulled off the front
and looking into the
rest of it)**

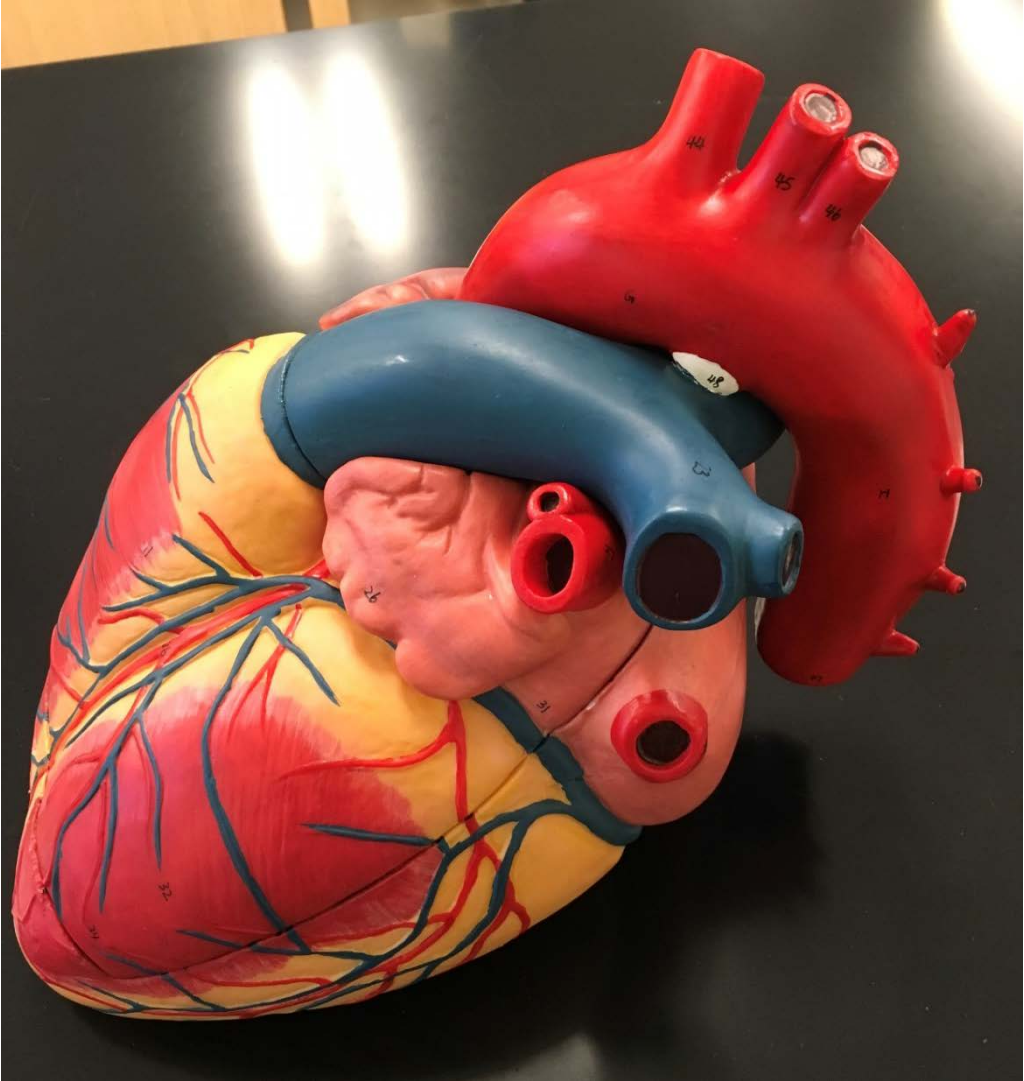


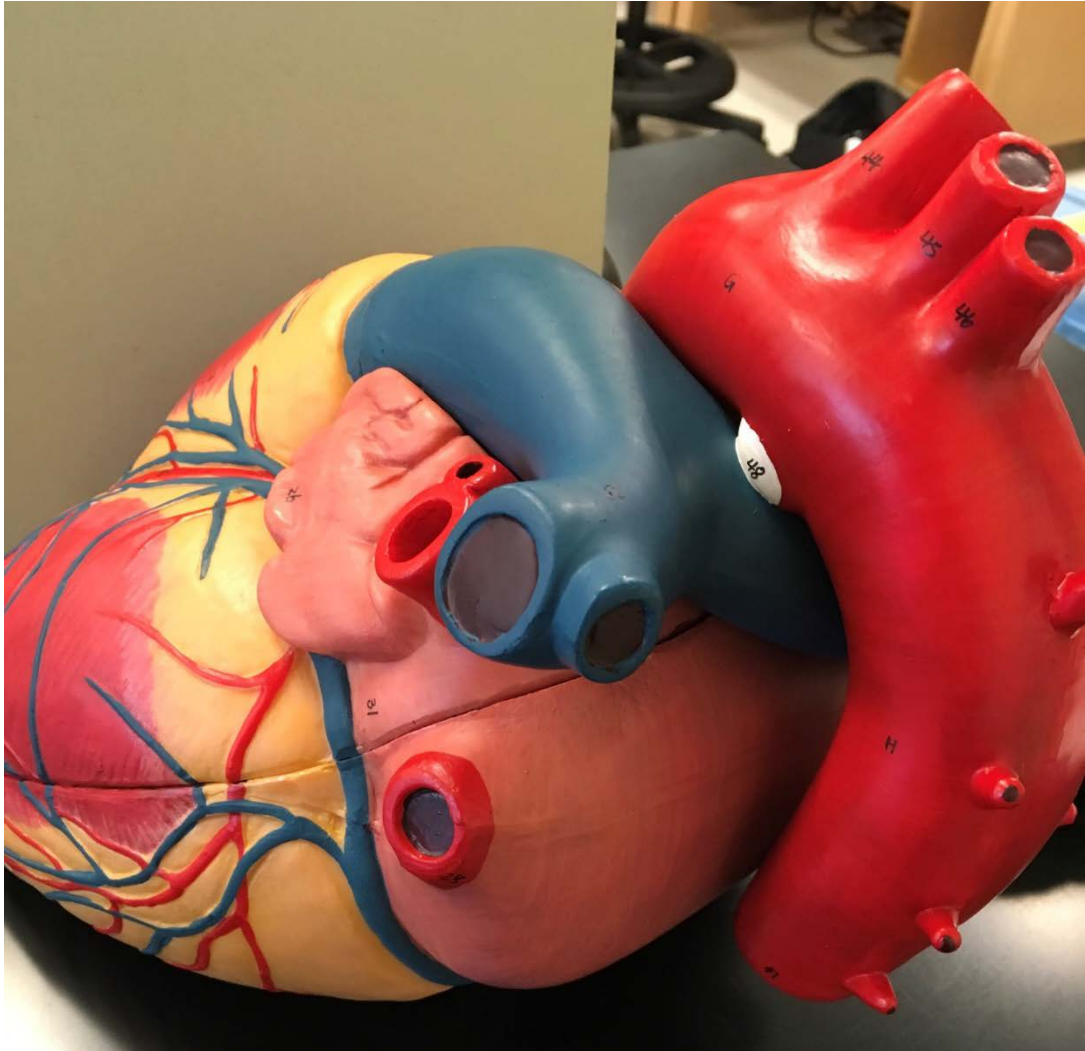

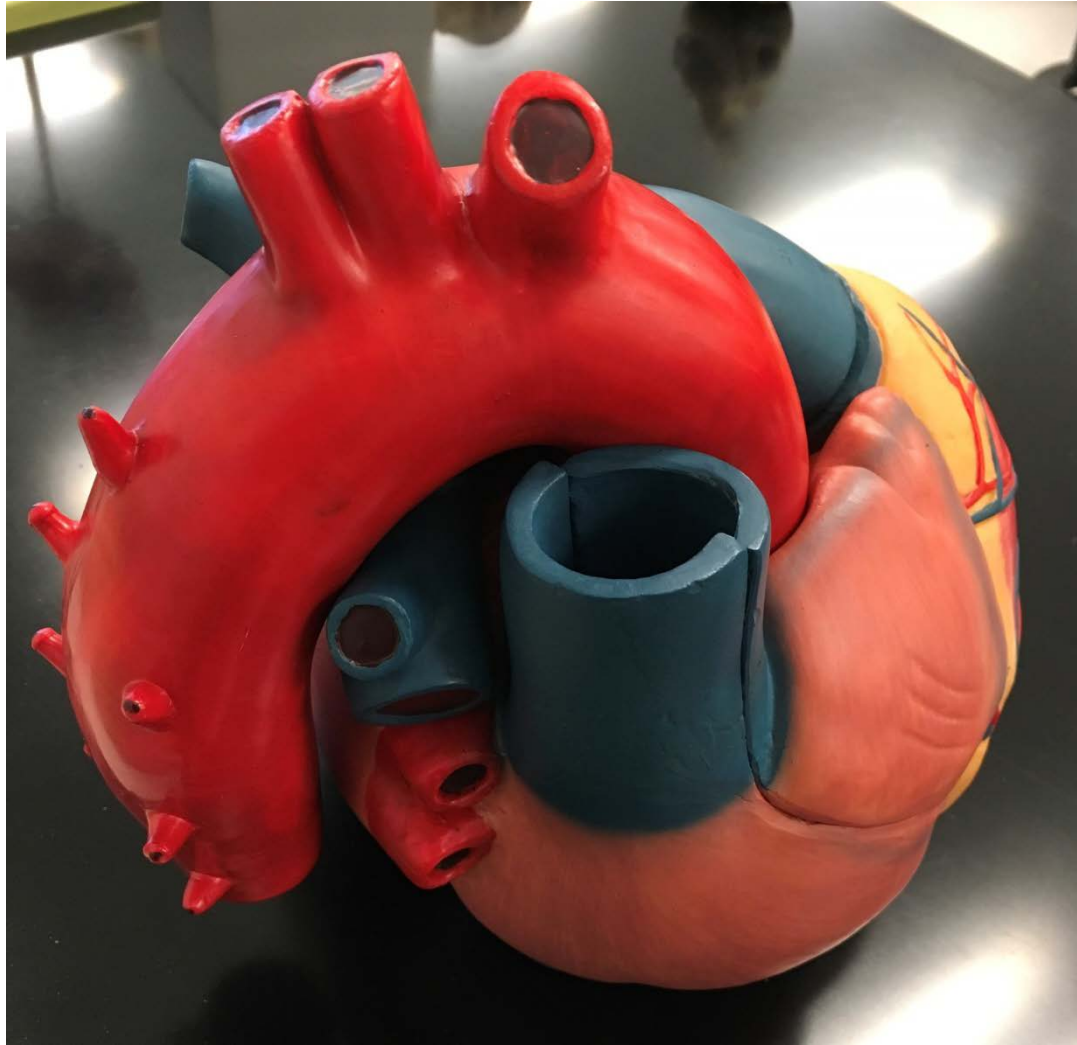


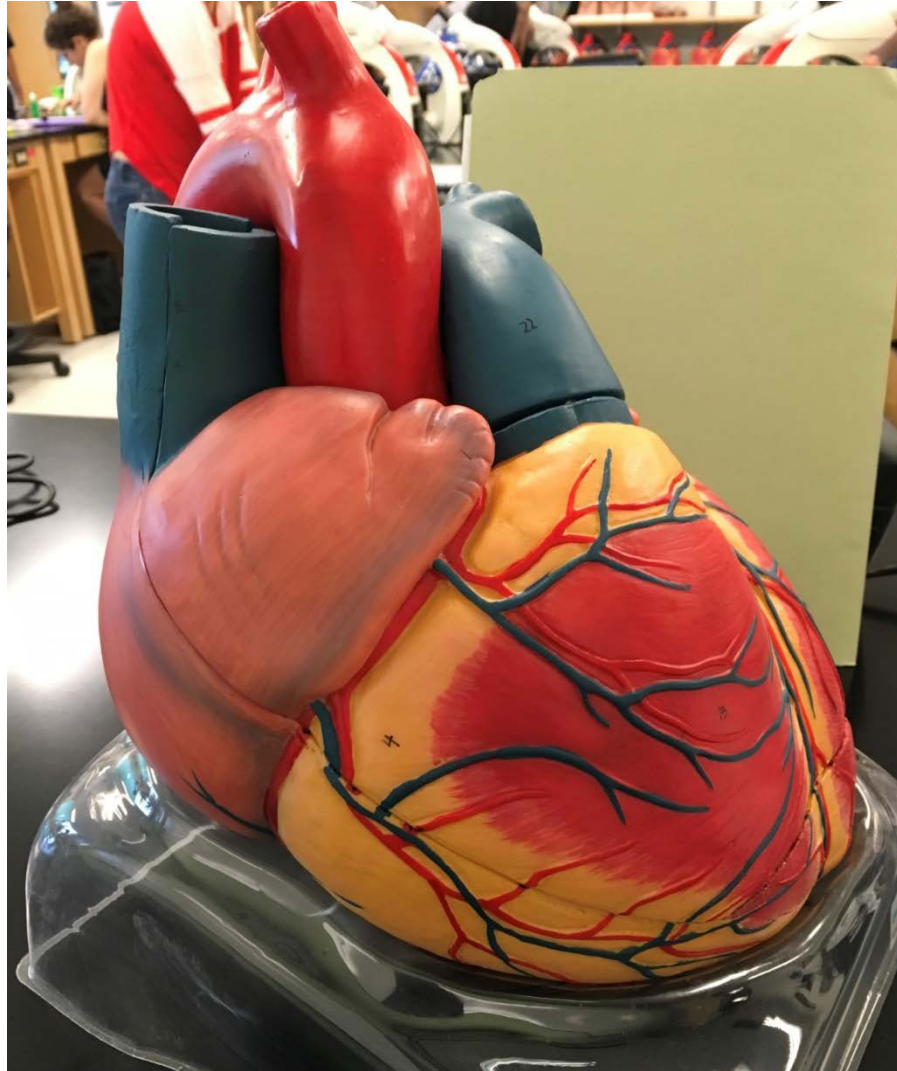
**Enlarged Human Heart
(Intact)**

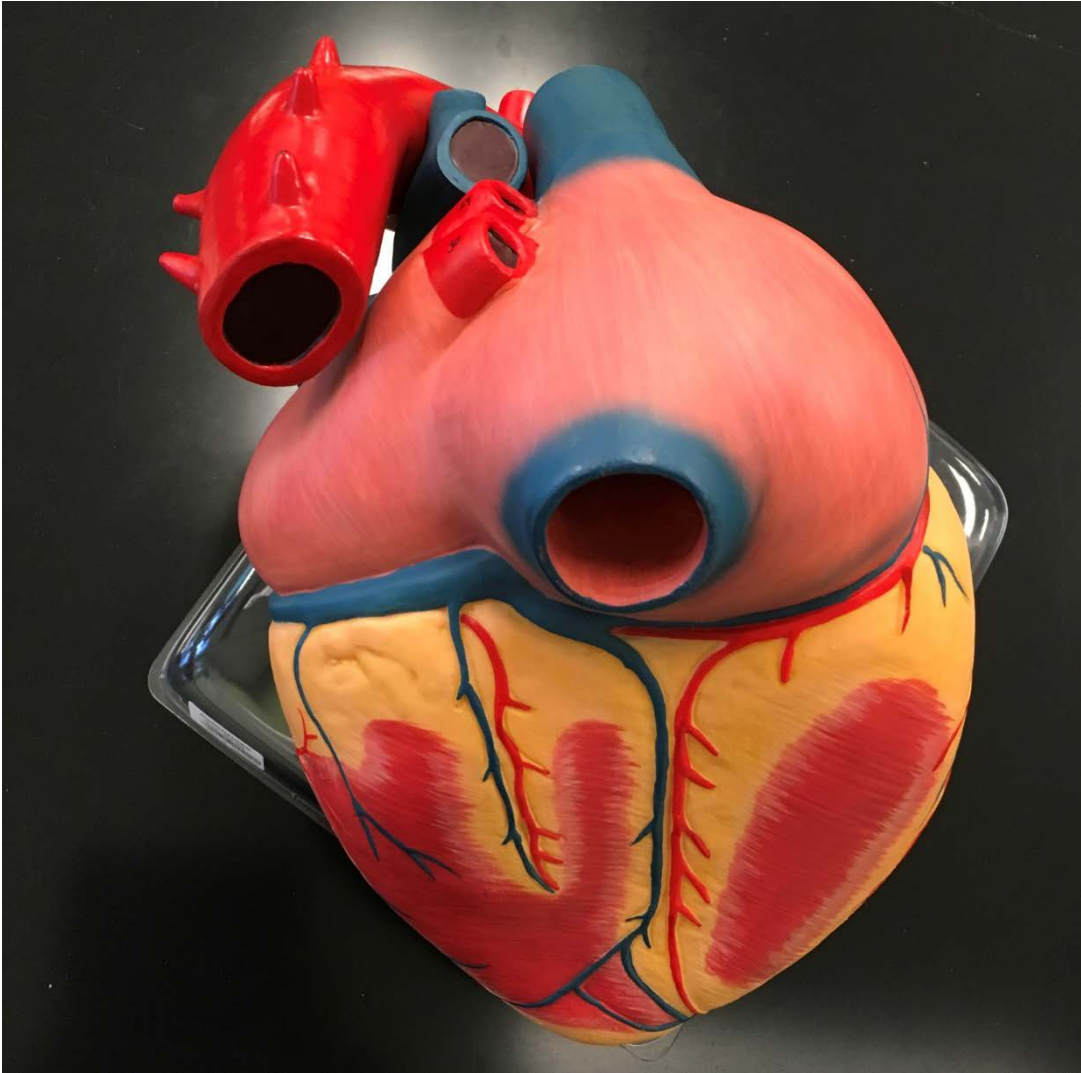


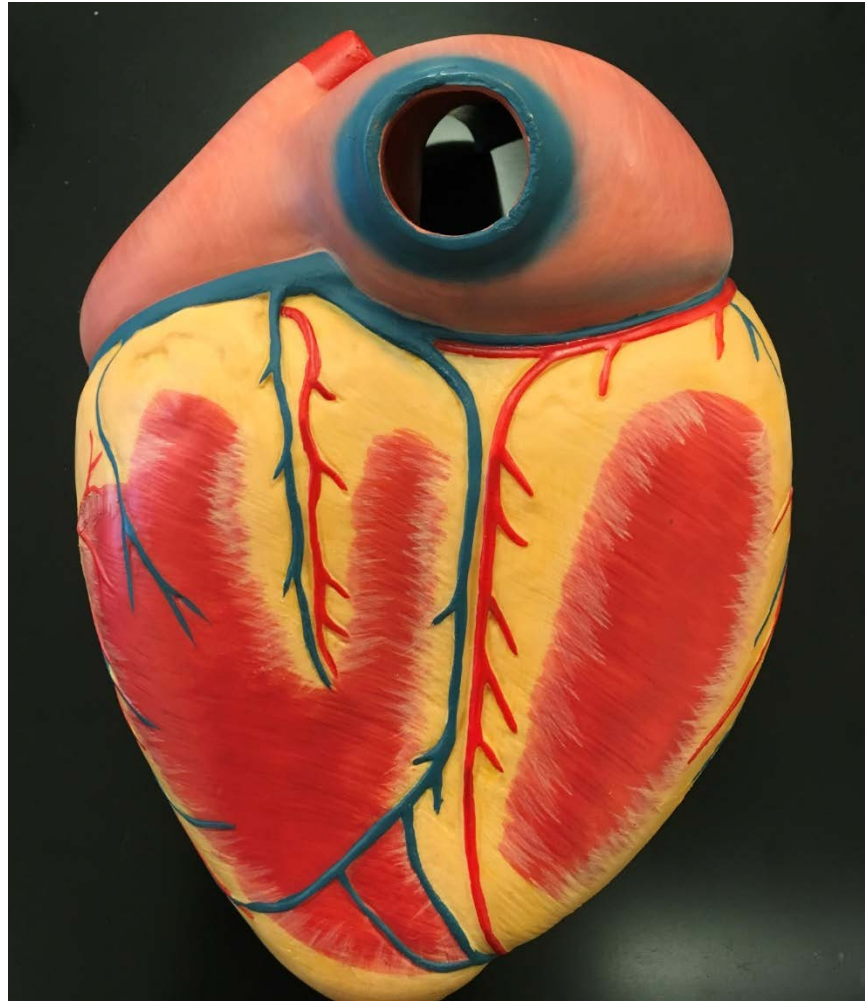


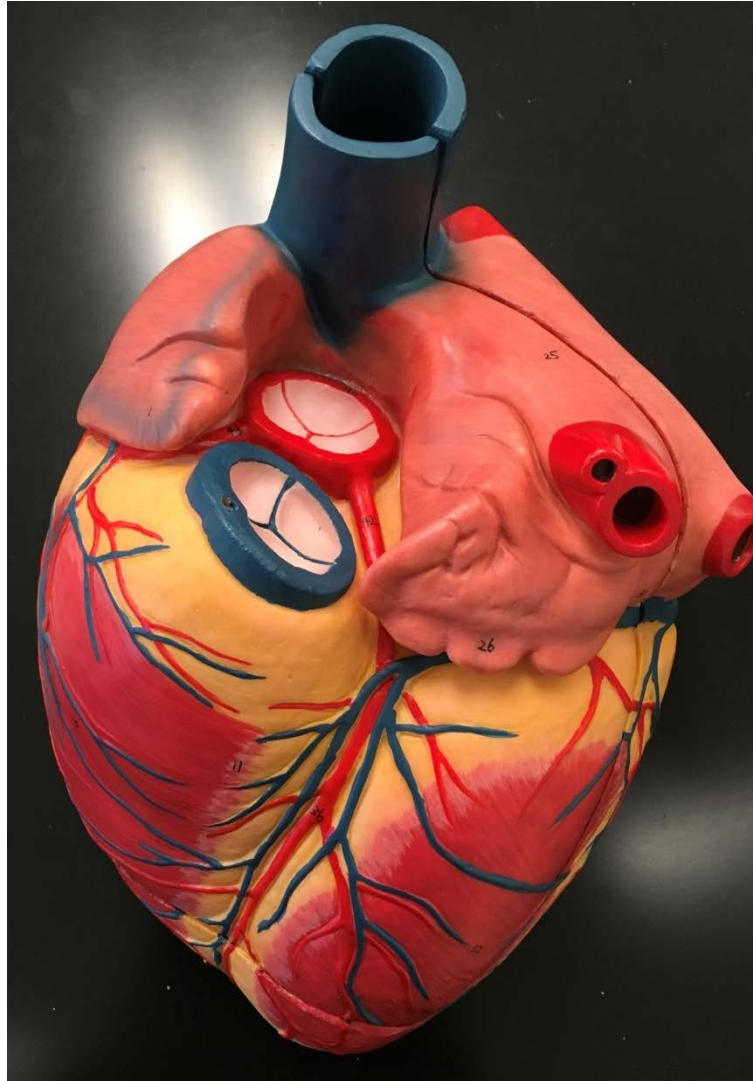


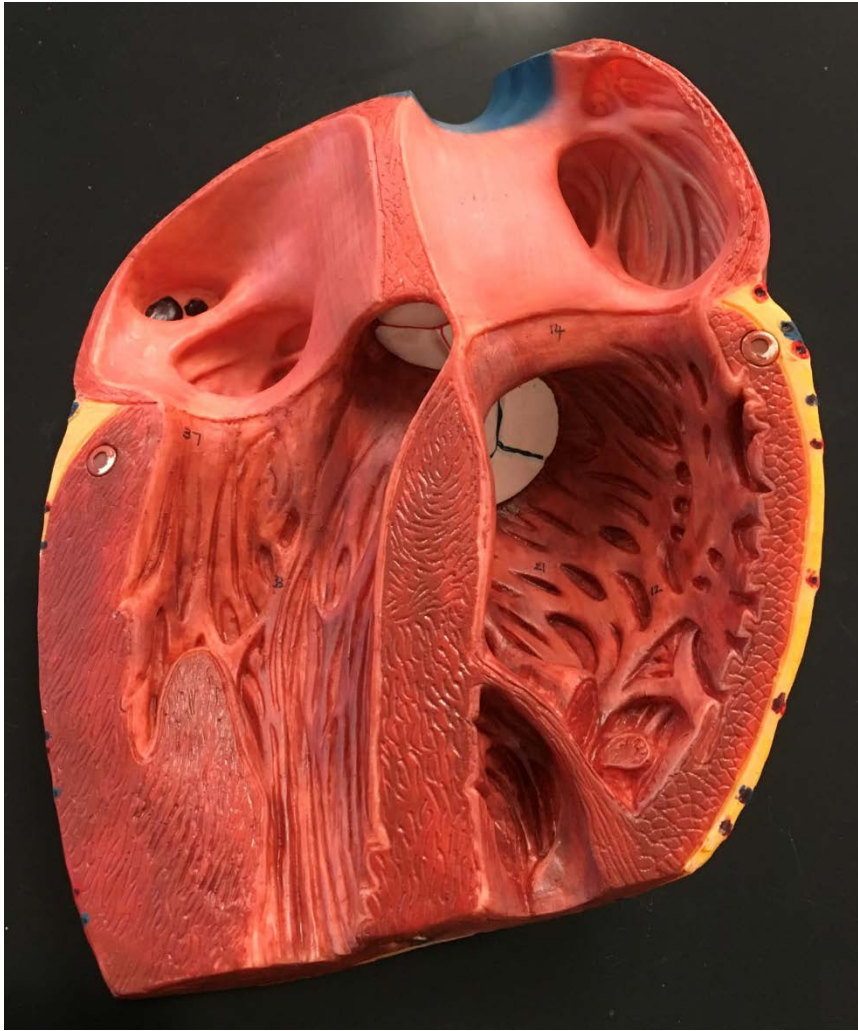




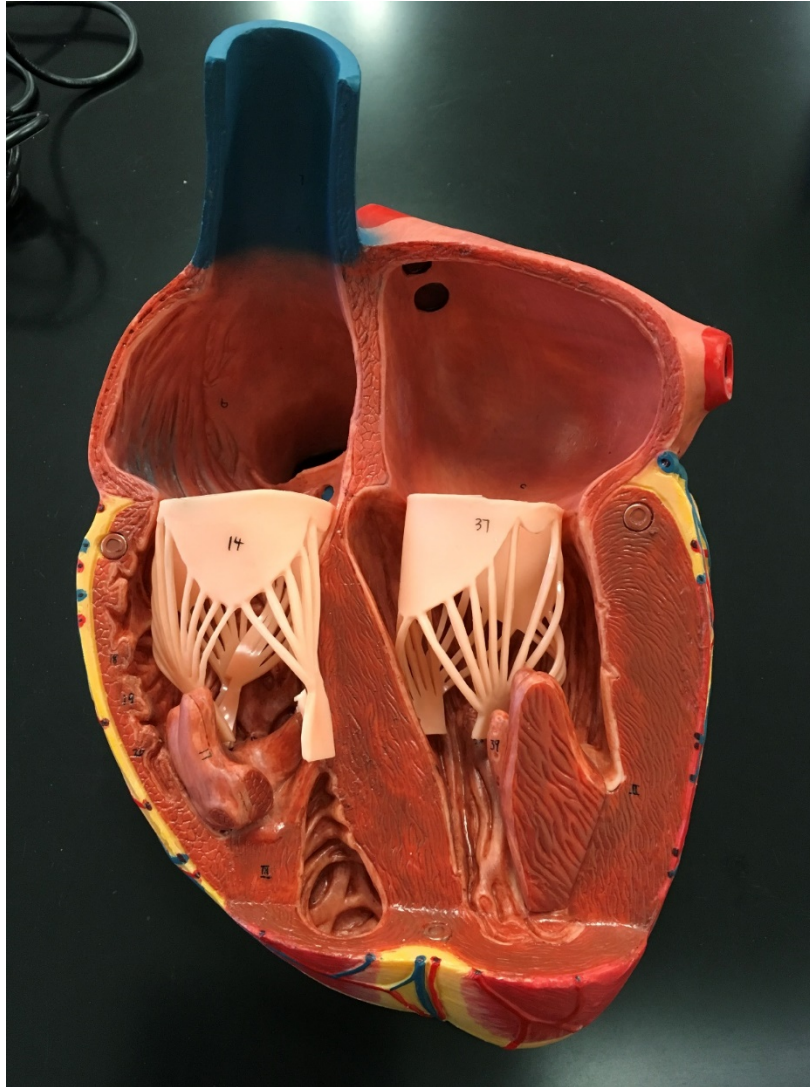




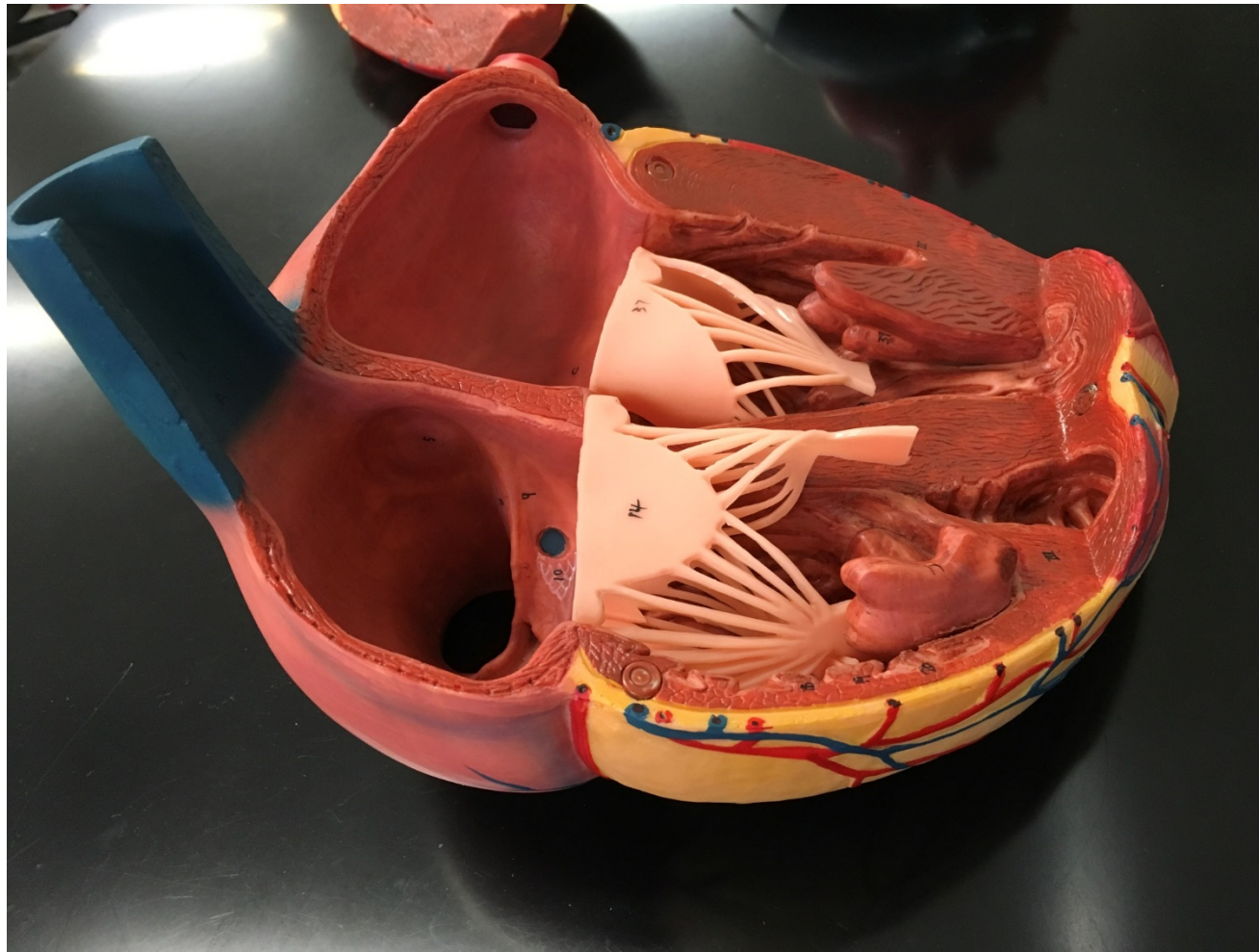**Enlarged Human Heart
(Superior Blood Vessels
Removed)**



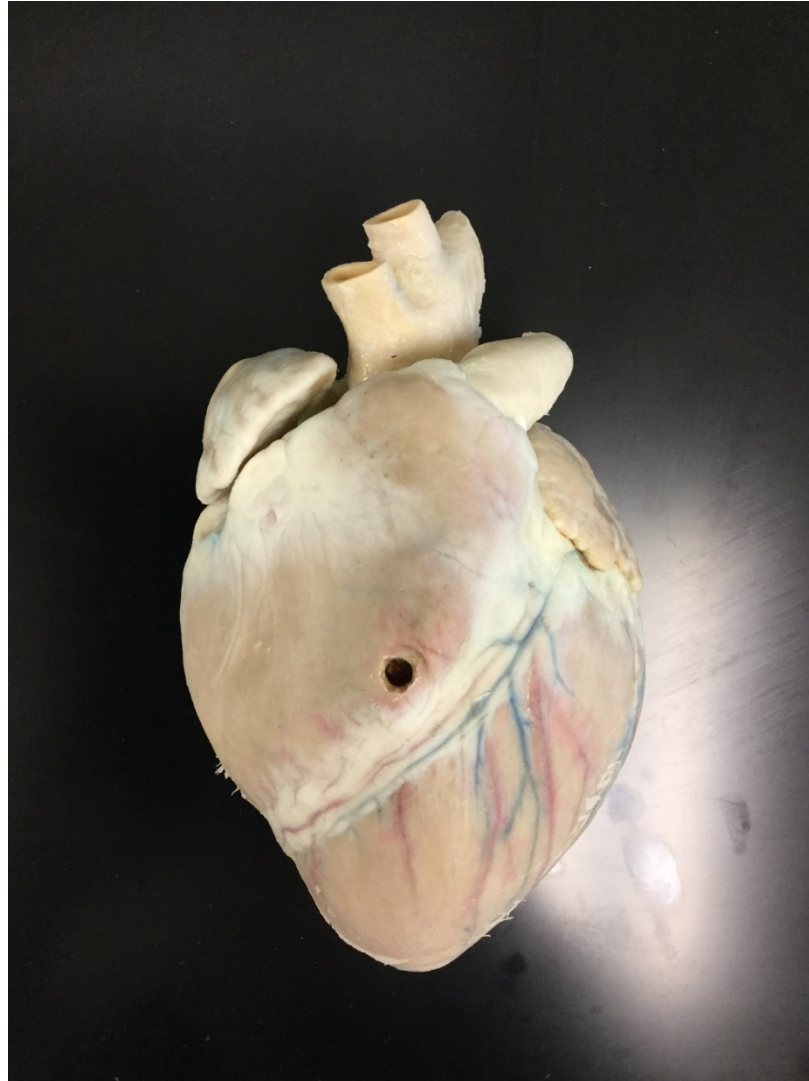
**Enlarged Human Heart
(Anterior Side Removed
with view into anterior
half)**



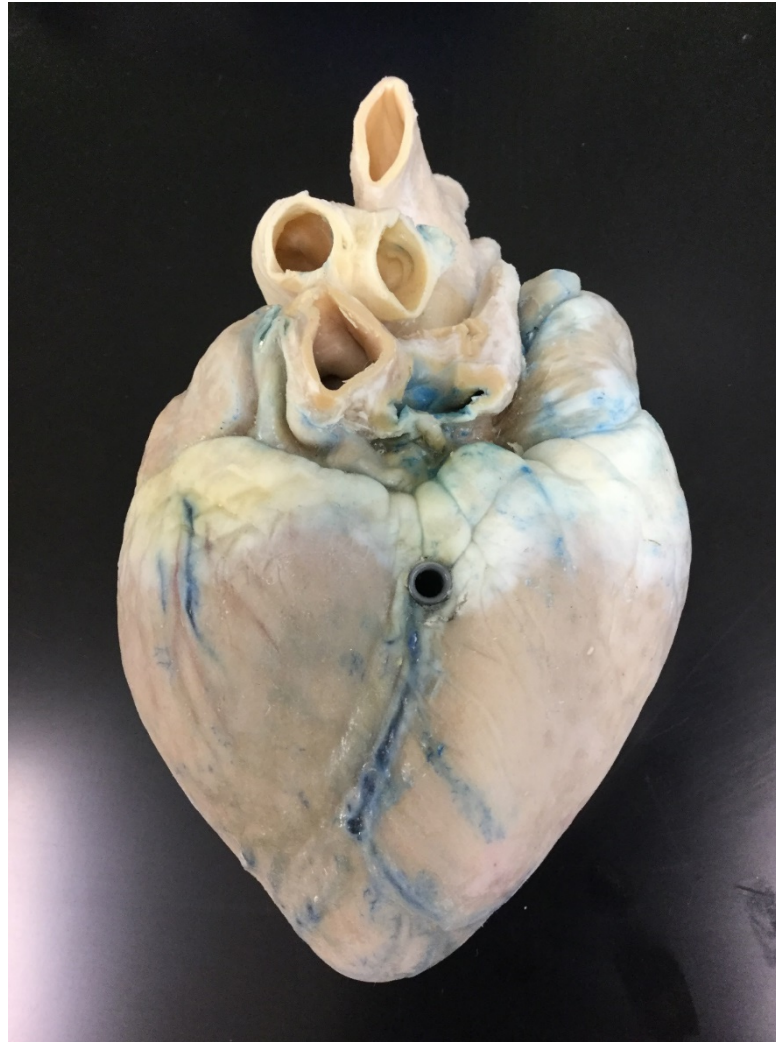
**Enlarged Human Heart
(Anterior Side Removed
with view into posterior
half)**



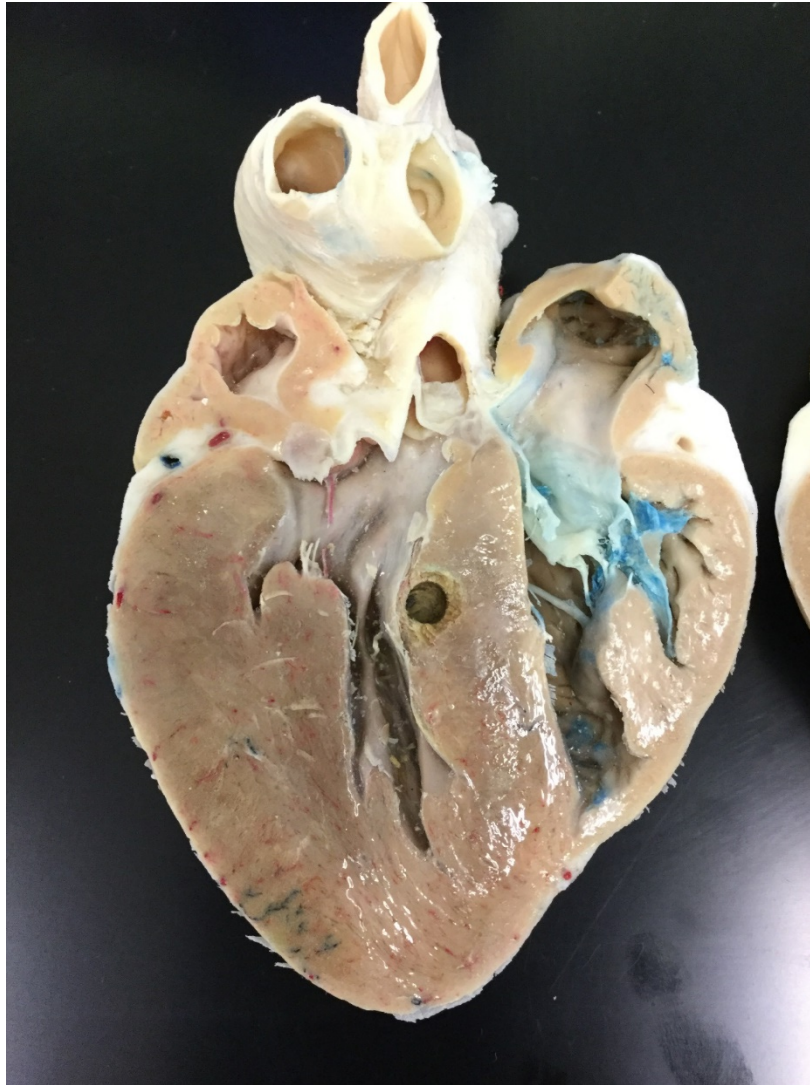**Enlarged Human Heart
(Anterior Side Removed
with view into posterior
half)**



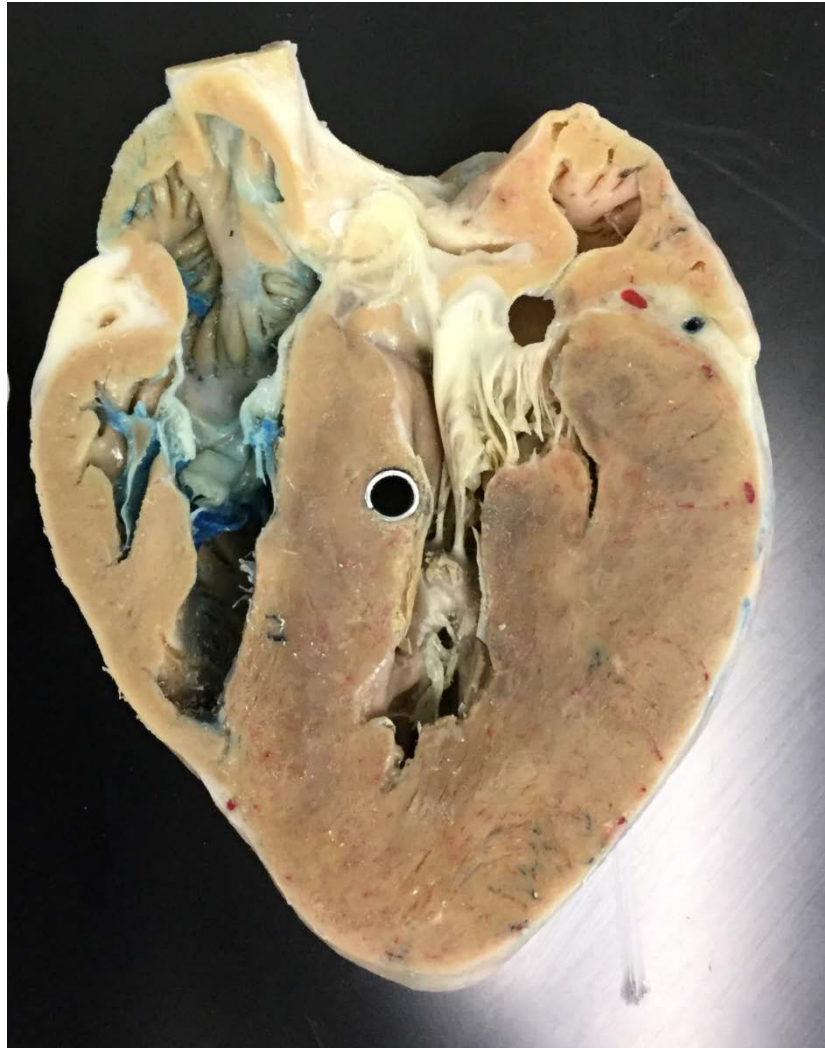
Real Animal Heart



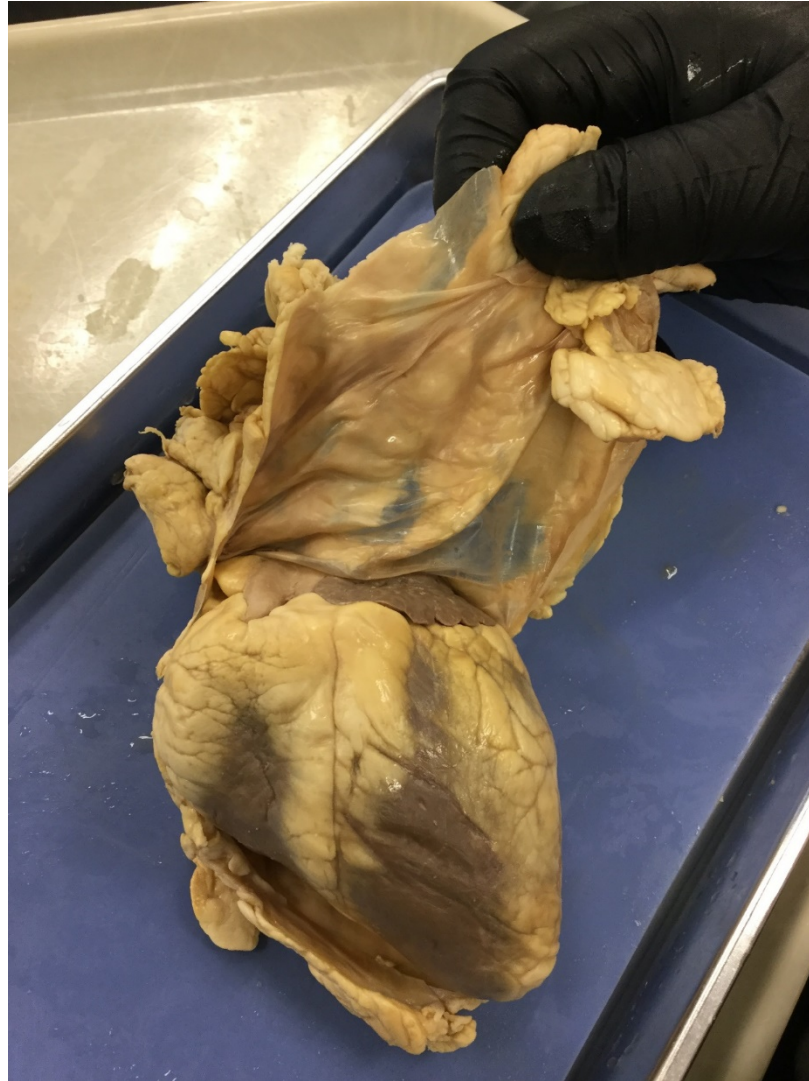Real Animal Heart



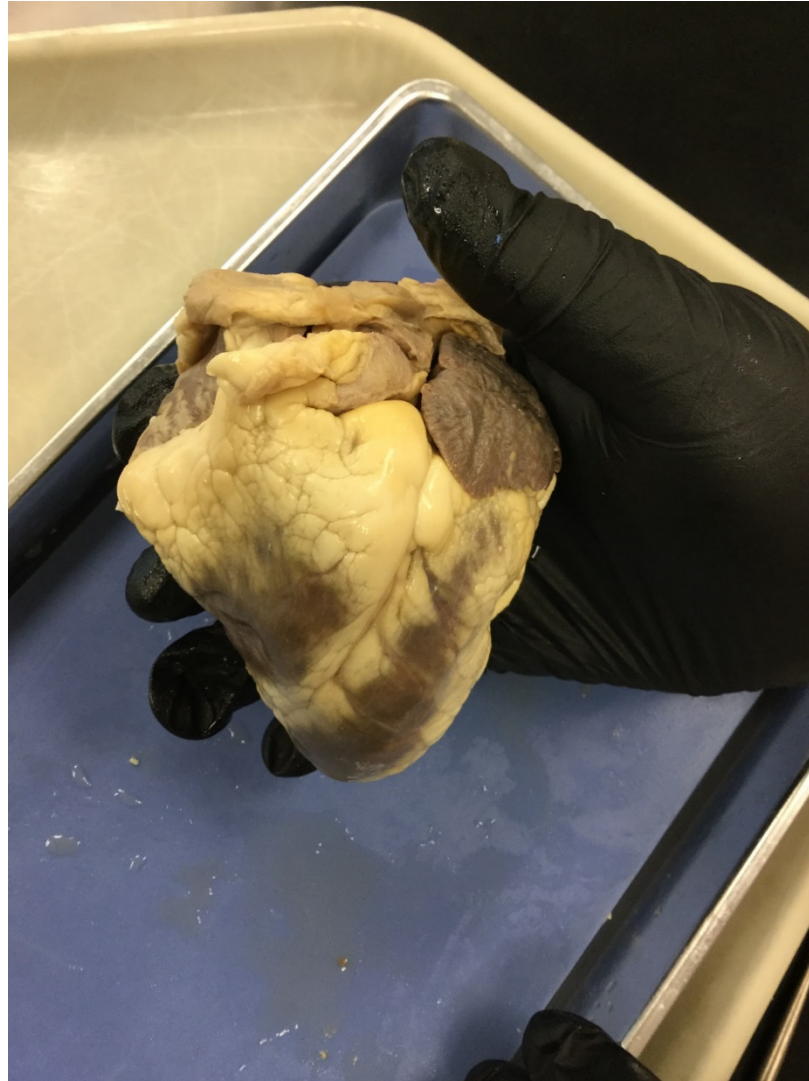
Real Animal Heart



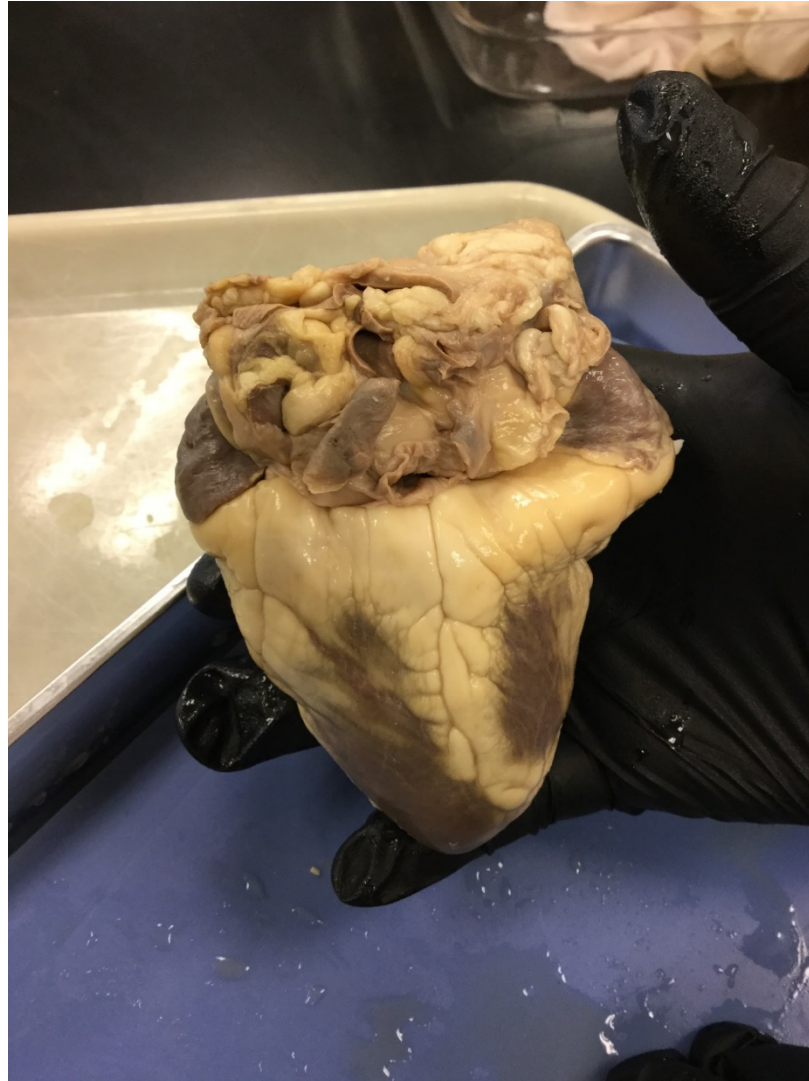
Real Animal Heart



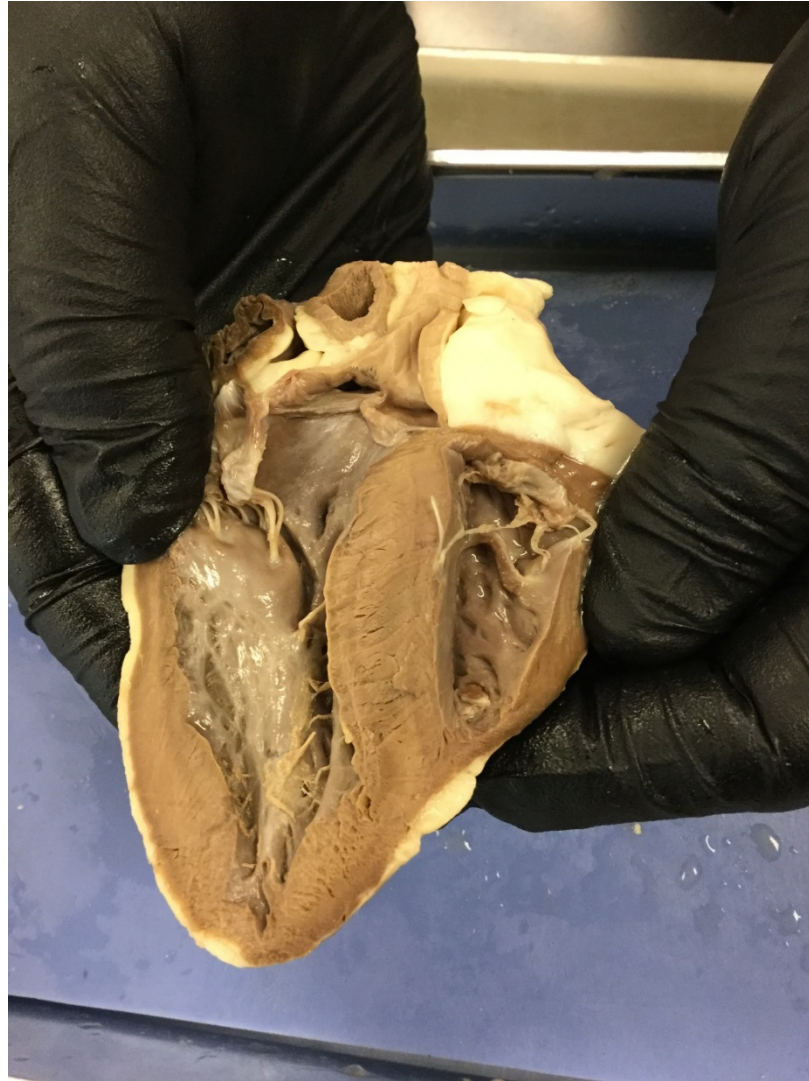**Real Animal Heart
(Dissected)**



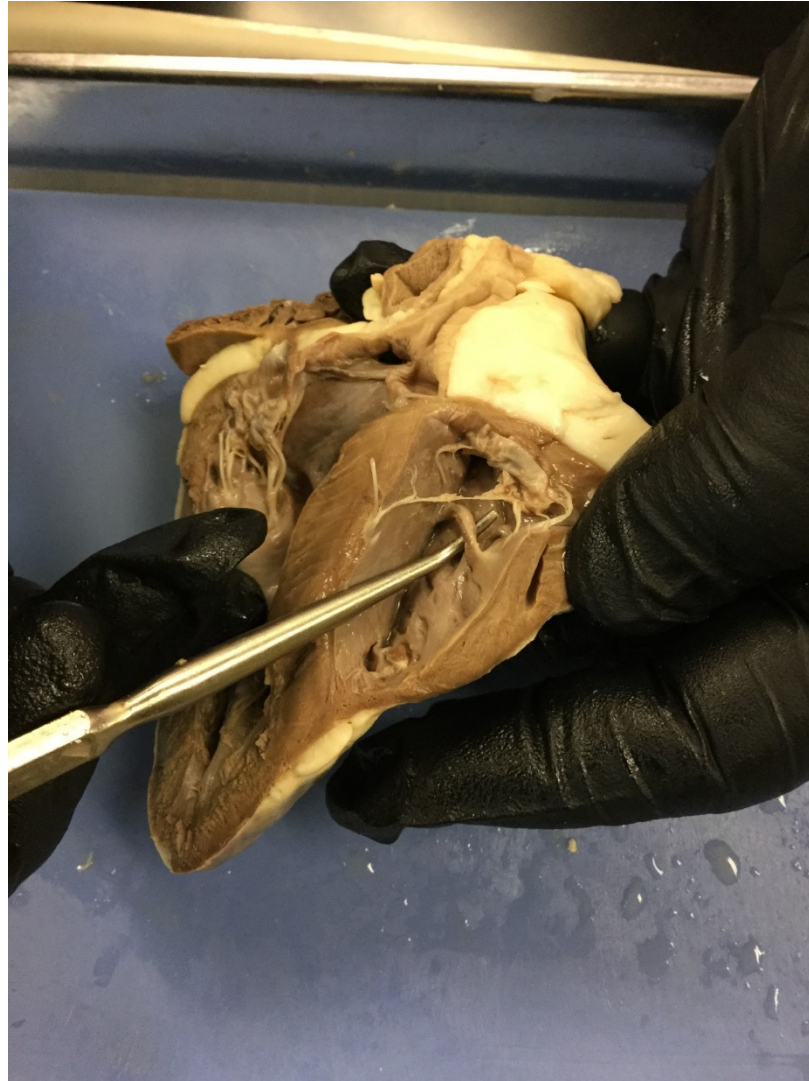**Real Animal Heart
(Dissected)**



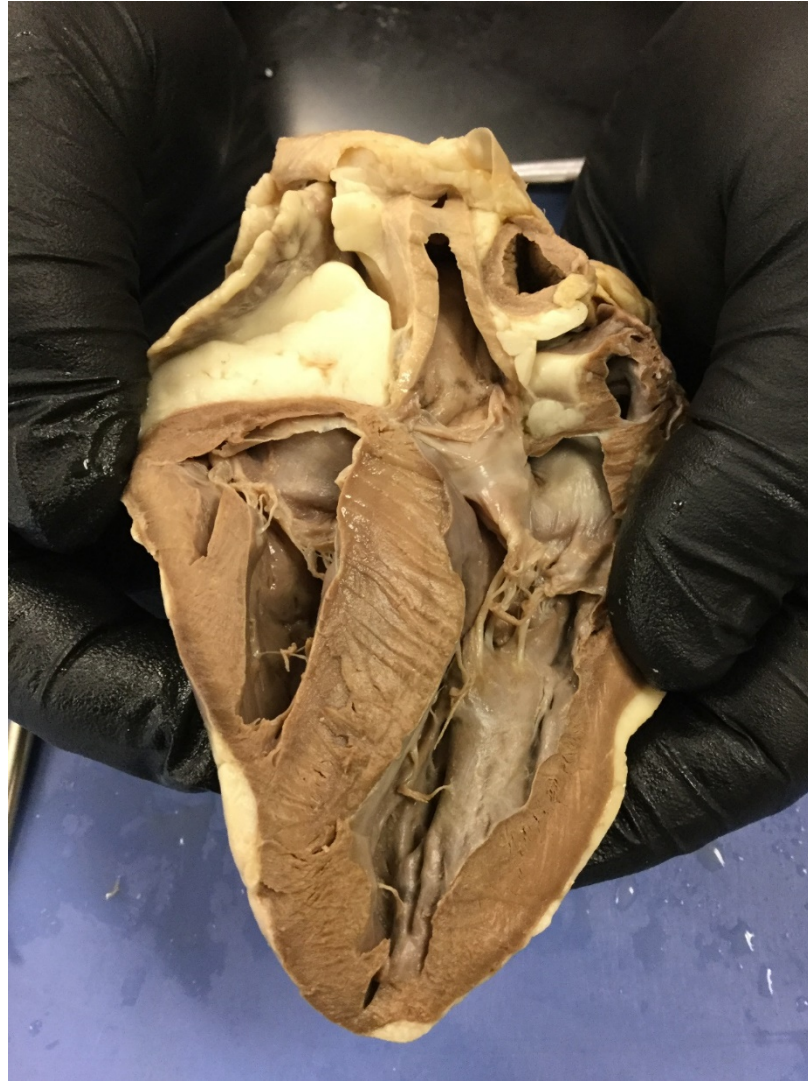
**Real Animal Heart
(Dissected)**



**Real Animal Heart
(Dissected)**



**Real Animal Heart
(Dissected)**



**Real Animal Heart
(Dissected)**

EKG Lab: No Images Needed...see
separate handout for this lab

Respiratory Anatomy (and Histology)

Use the following pictures to help you identify terms from the lab term handout.

***You always only need to know the terms listed in the lab term handout!

Another good resource for histology is the Olexik website:

http://faculty.montgomerycollege.edu/wolexik/205_histology_page.htm

Another good resource is the Visible Body ATLAS app: <http://atlas.visiblebody.com>

Don't forget that to use the link to download the atlas to a personal device, the device must first be connected to the MCPA Wi-Fi at the Rockville campus.

Figure 22.1 The major respiratory organs in relation to surrounding structures.

Structural Classification:

- 1. Upper Resp. Sys.
- 2. Lower Resp. Sys.

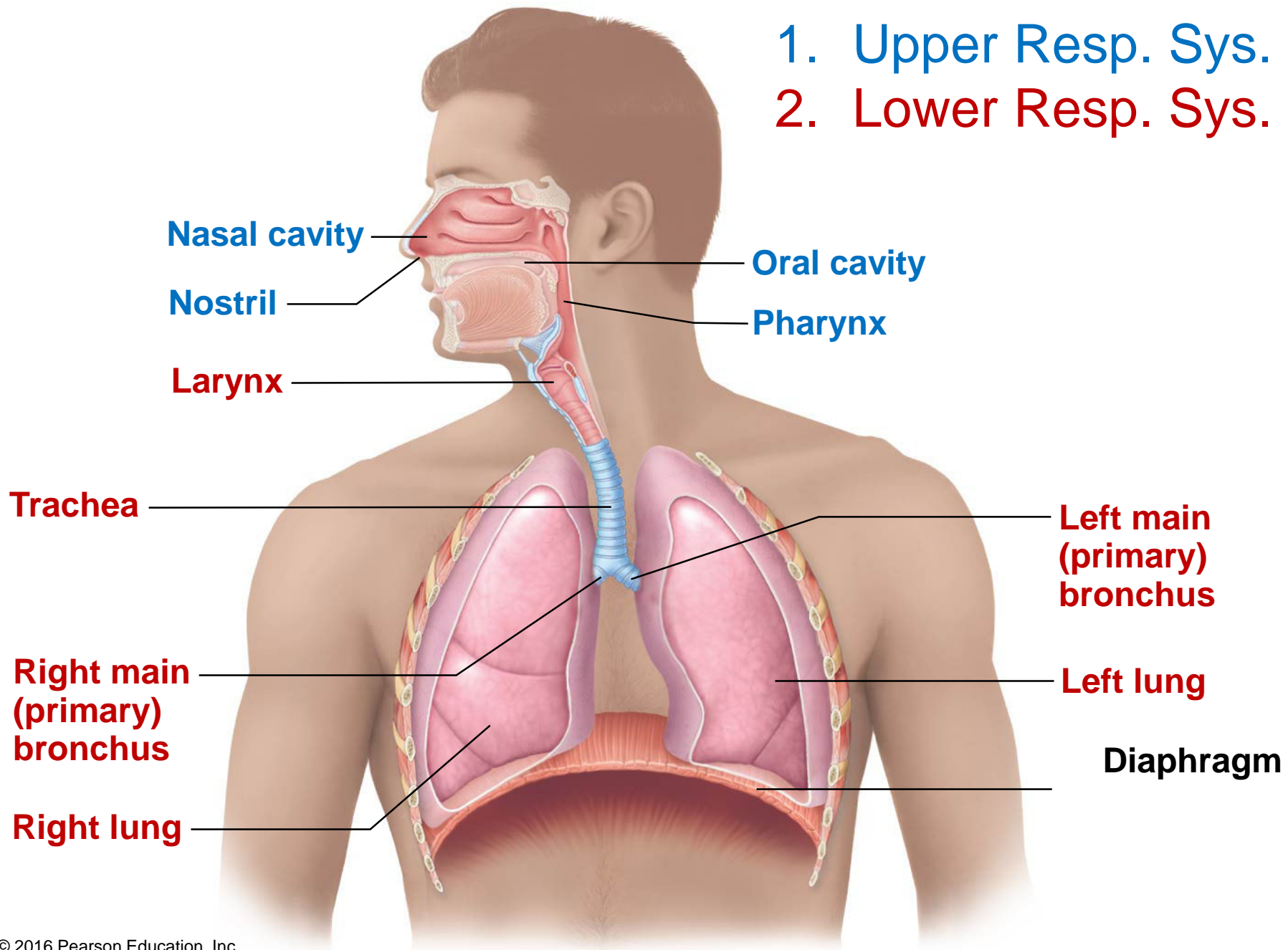


Figure 22.8 Conducting zone passages.

Structural Classification:

- 1. Upper Resp. Sys.
- 2. Lower Resp. Sys.

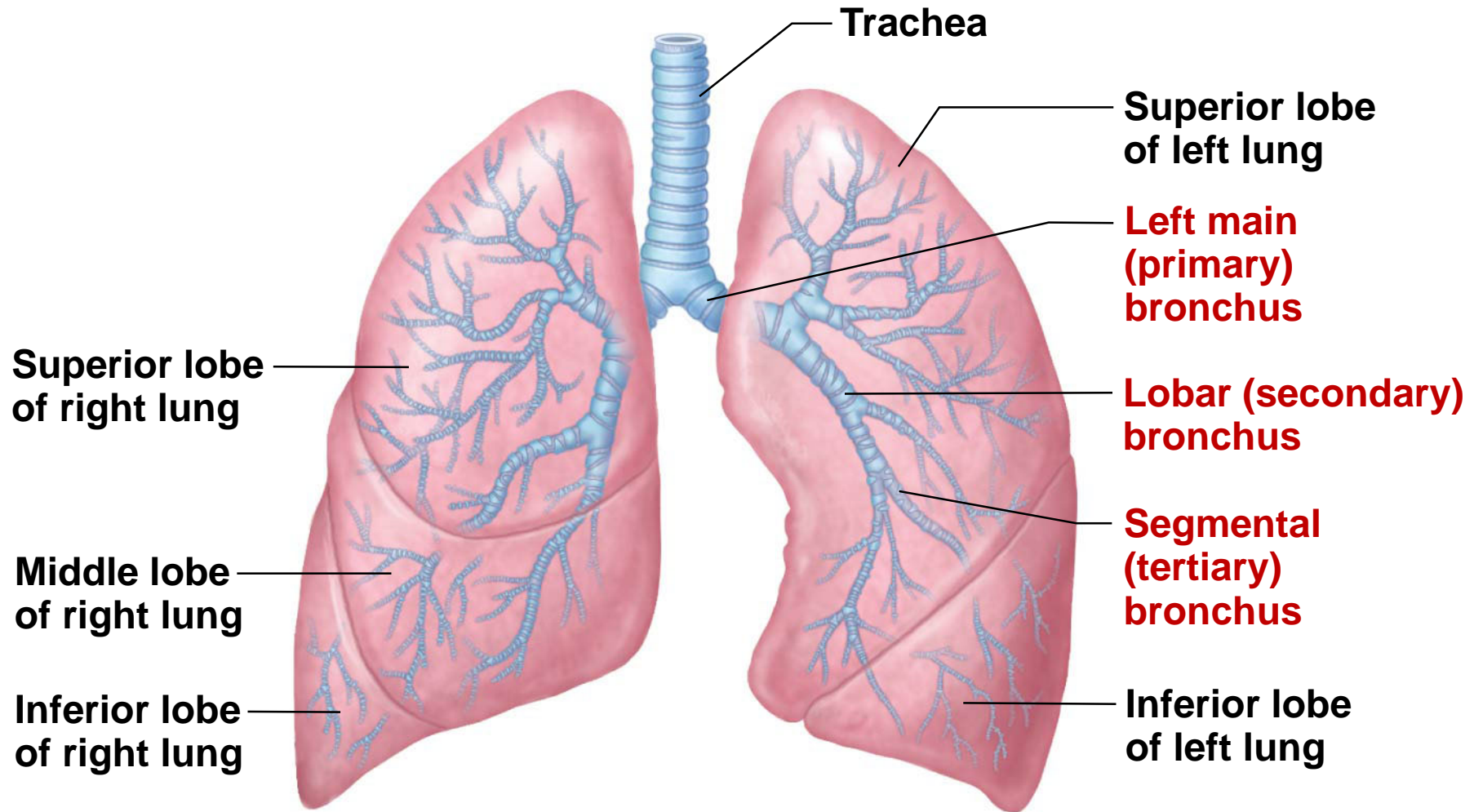


Figure 22.8 Conducting zone passages.

Structural Classification:

- 1. Upper Resp. Sys.
- 2. Lower Resp. Sys.

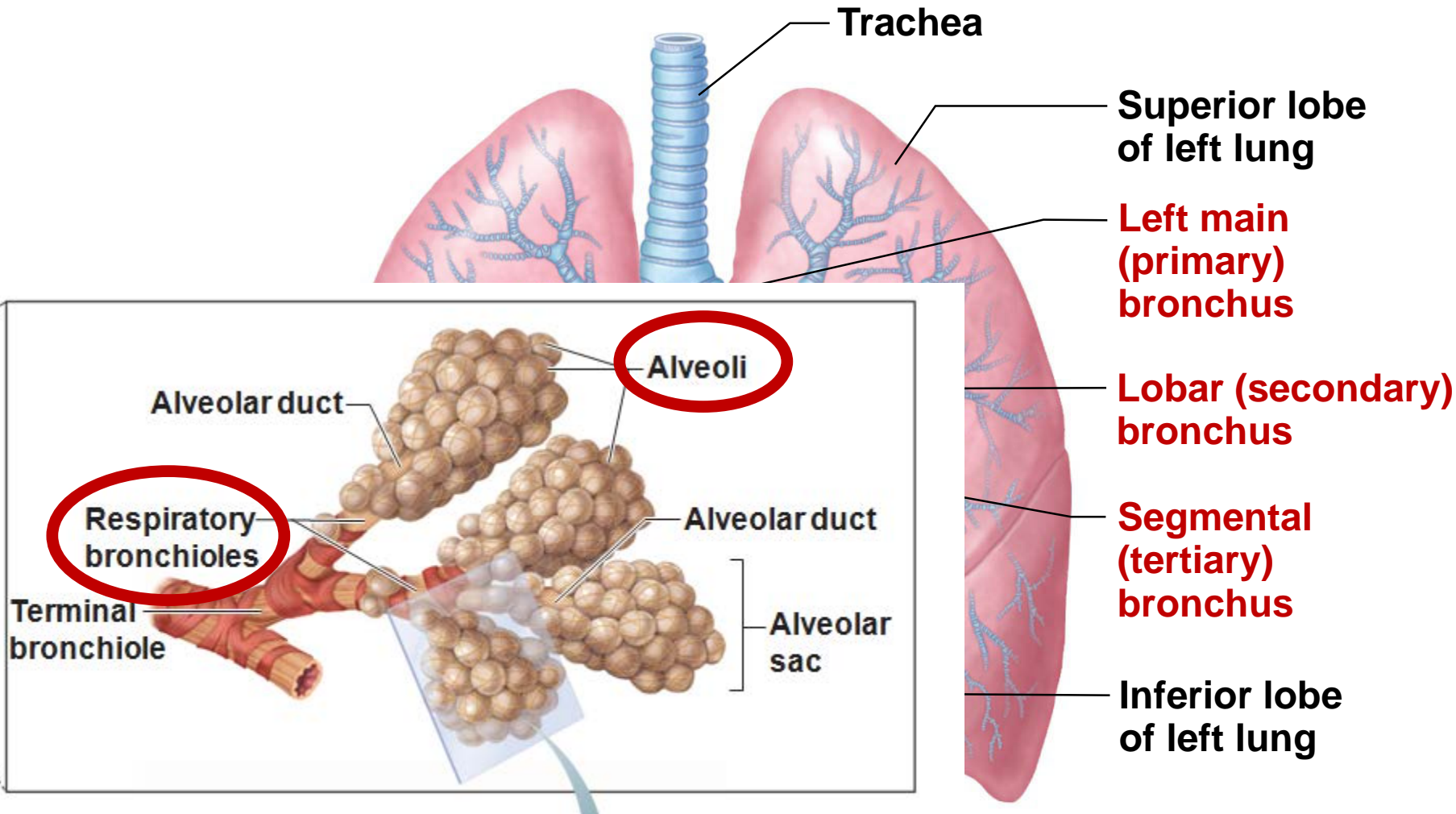


Figure 22.3a The nasal cavity.

The Nose

Posterior nasal aperture (Posterior Nare)

Sphenoidal sinus

Cribriform plate of ethmoid bone

Frontal sinus

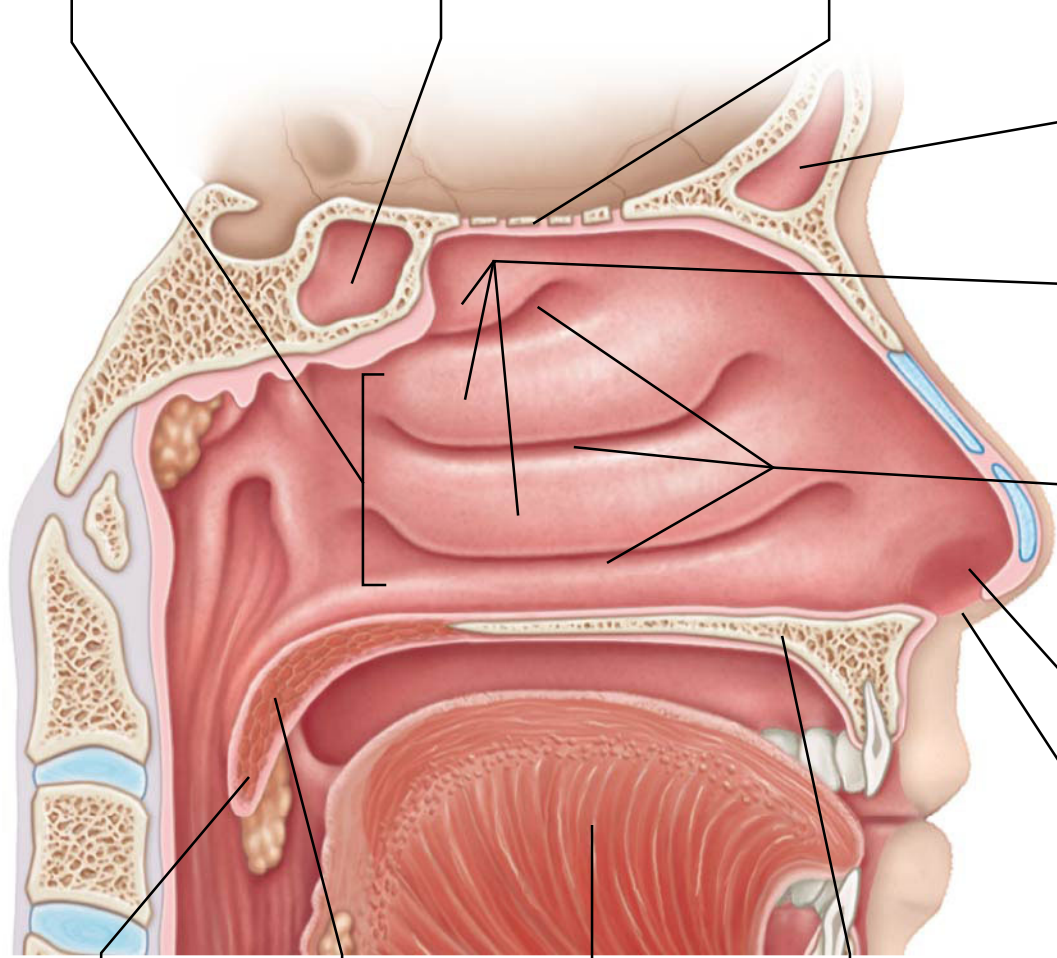
Nasal cavity

- **Nasal conchae (superior, middle and inferior)**

- **Nasal meatuses (superior, middle, and inferior)**

- **Nasal vestibule**

- **Nostril (Anterior Nare)**



Uvula

Soft palate

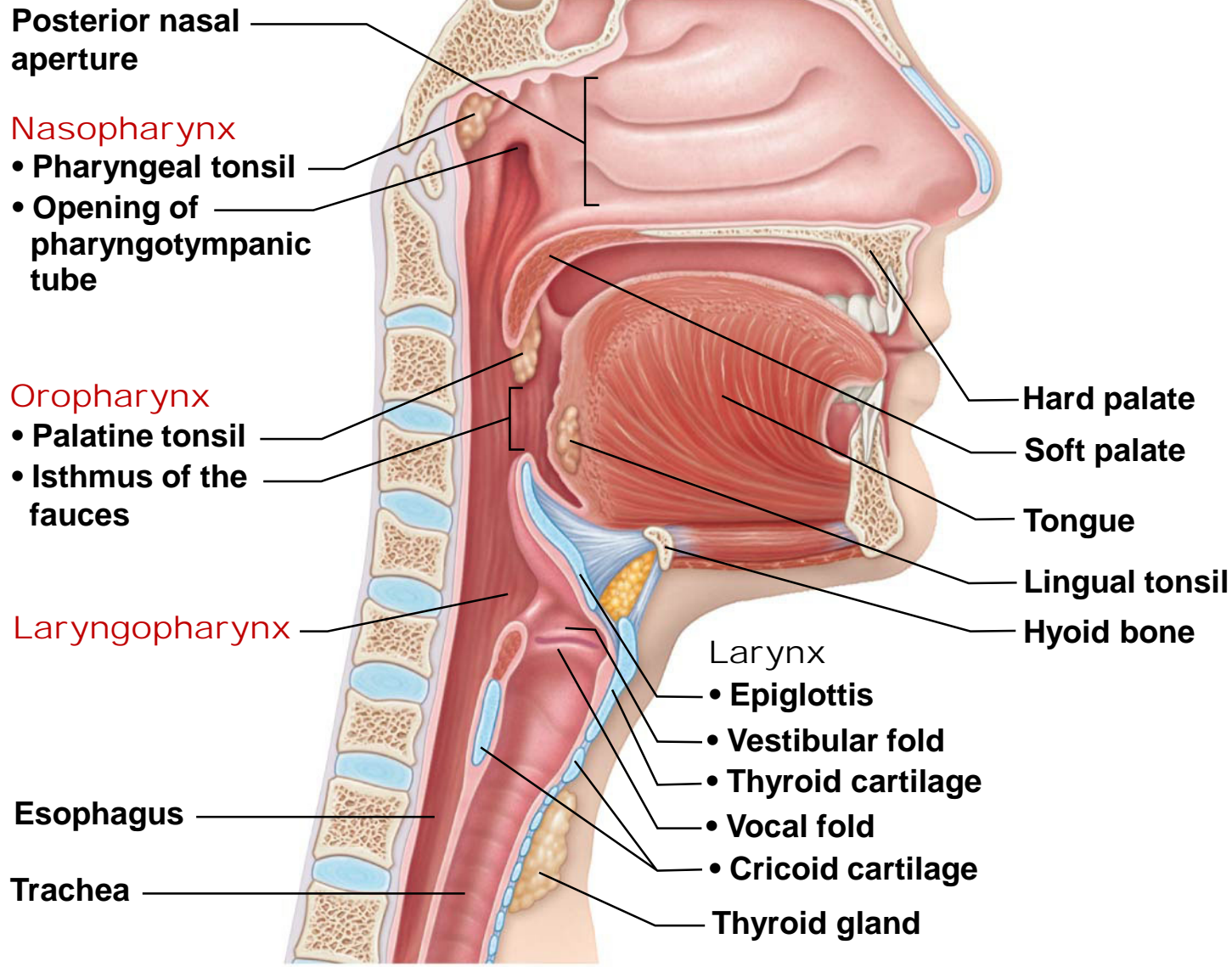
Tongue

Hard palate

(a)

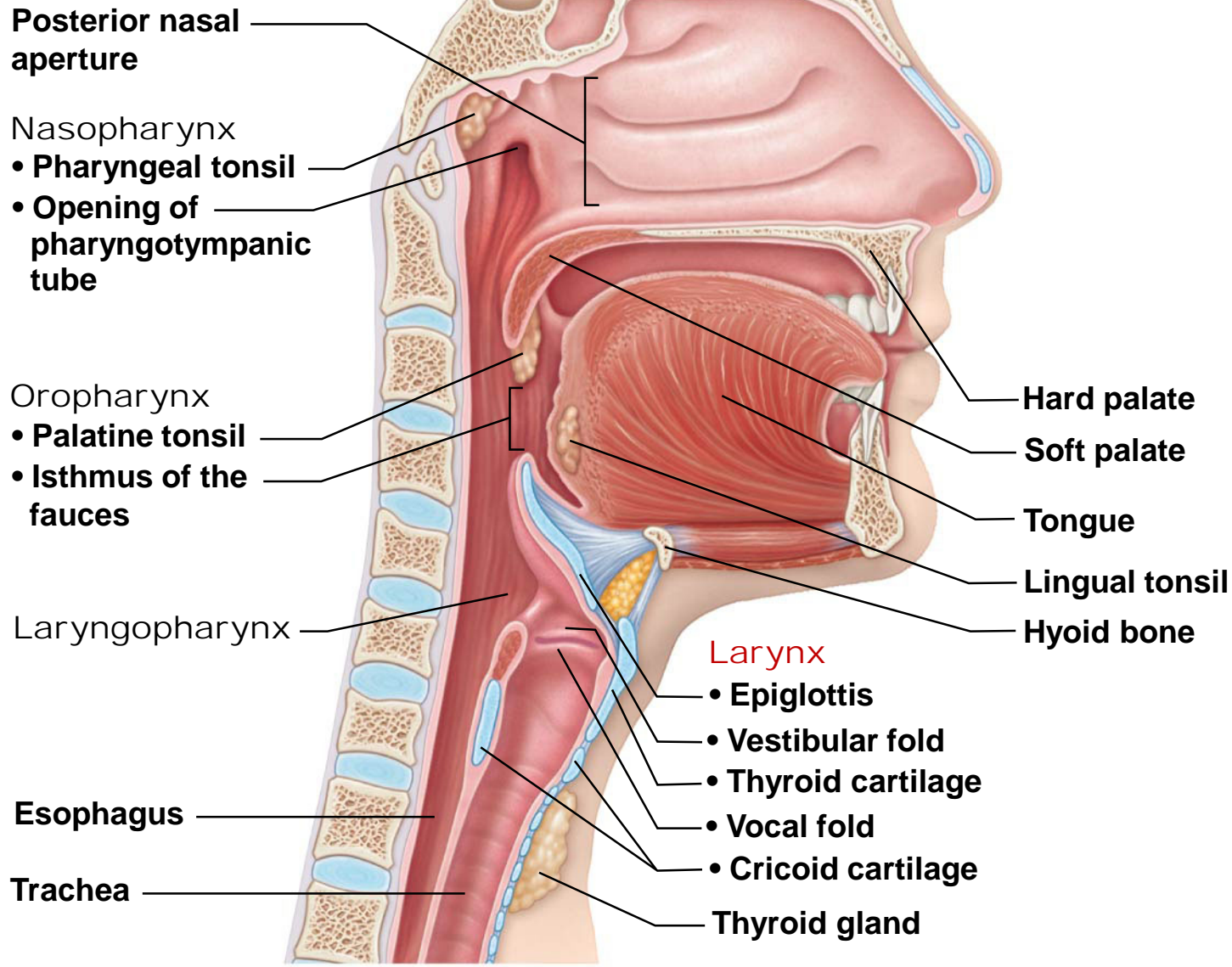
Figure 22.4b The pharynx, larynx, and upper trachea.

Pharynx

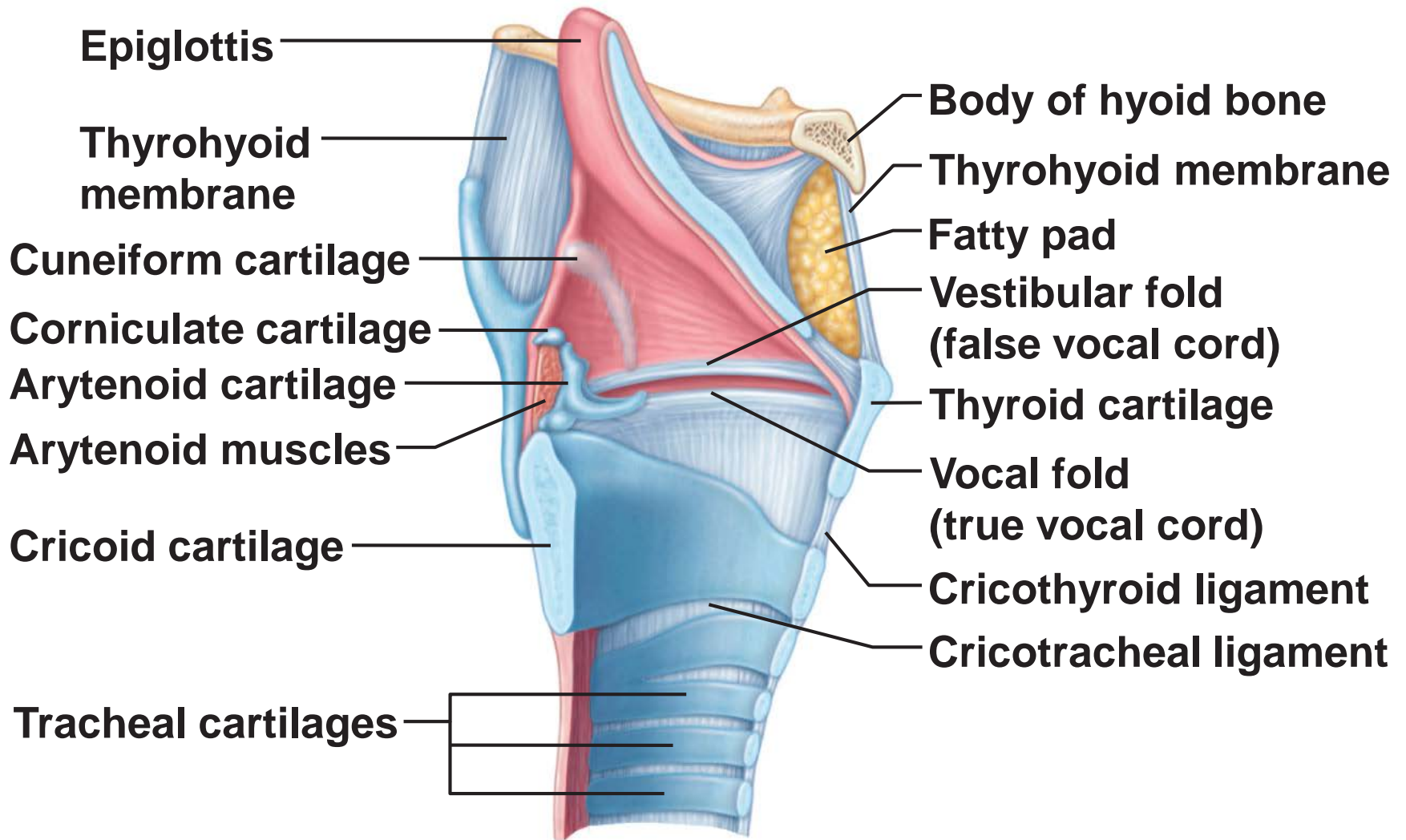


(b) Structures of the pharynx and larynx

Larynx



(b) Structures of the pharynx and larynx



(b) Sagittal view; anterior surface to the right

Trachea

- Windpipe

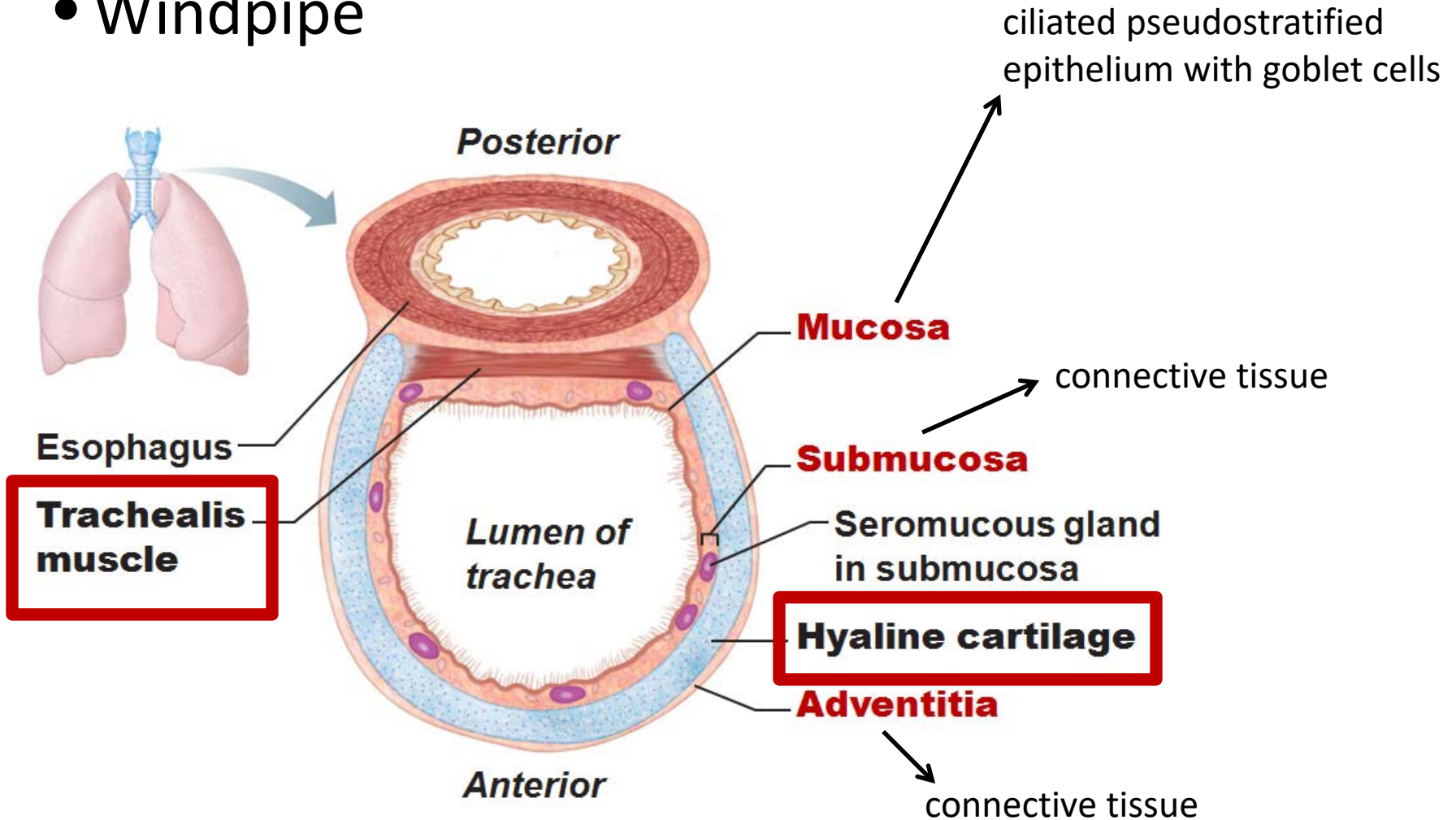
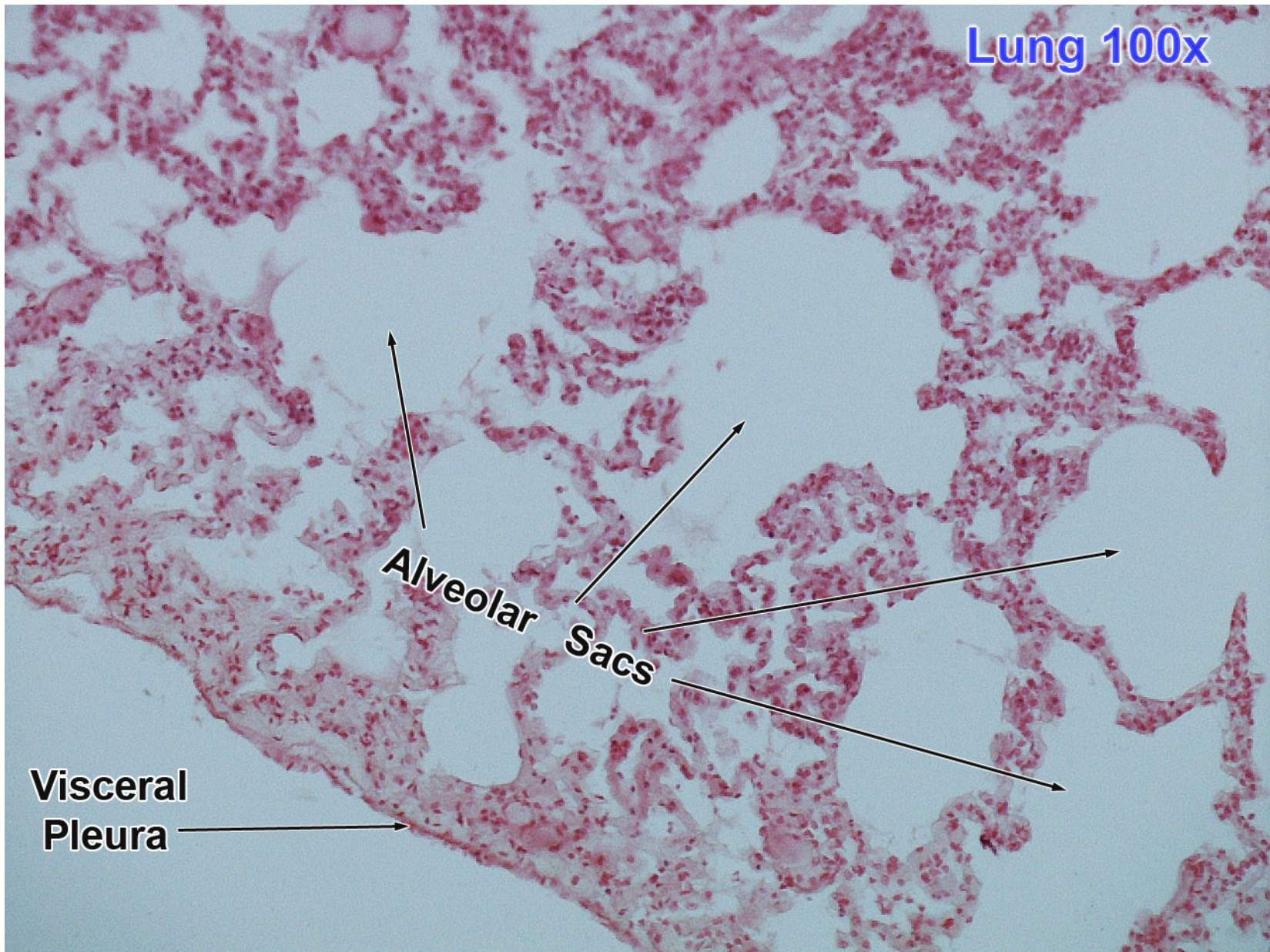


Figure 22.6a

Lung 100x



Alveolar Sacs

Visceral Pleura

Lung 40x

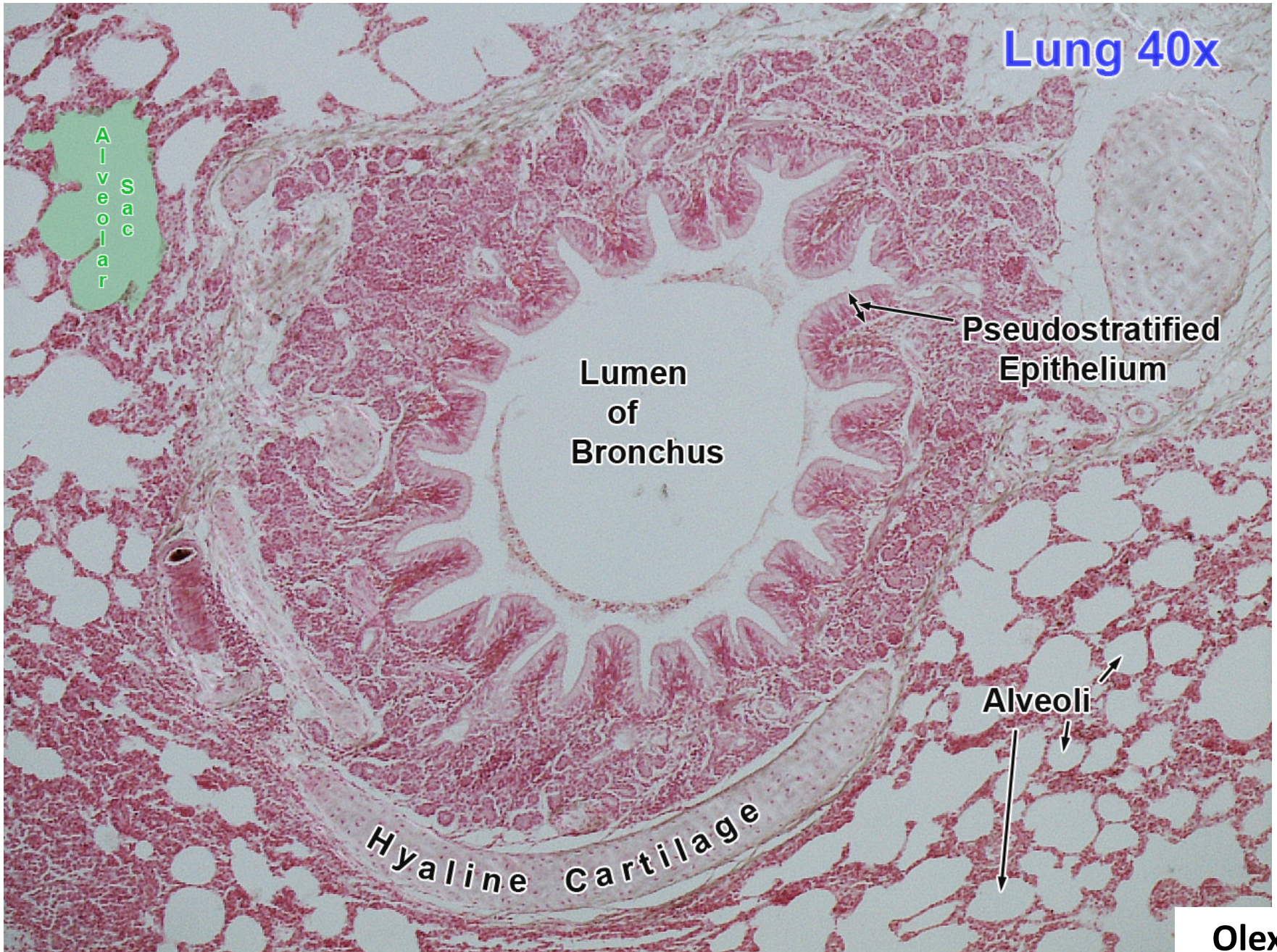
Alveolar Sac

Lumen of Bronchus

Pseudostratified Epithelium

Hyaline Cartilage

Alveoli

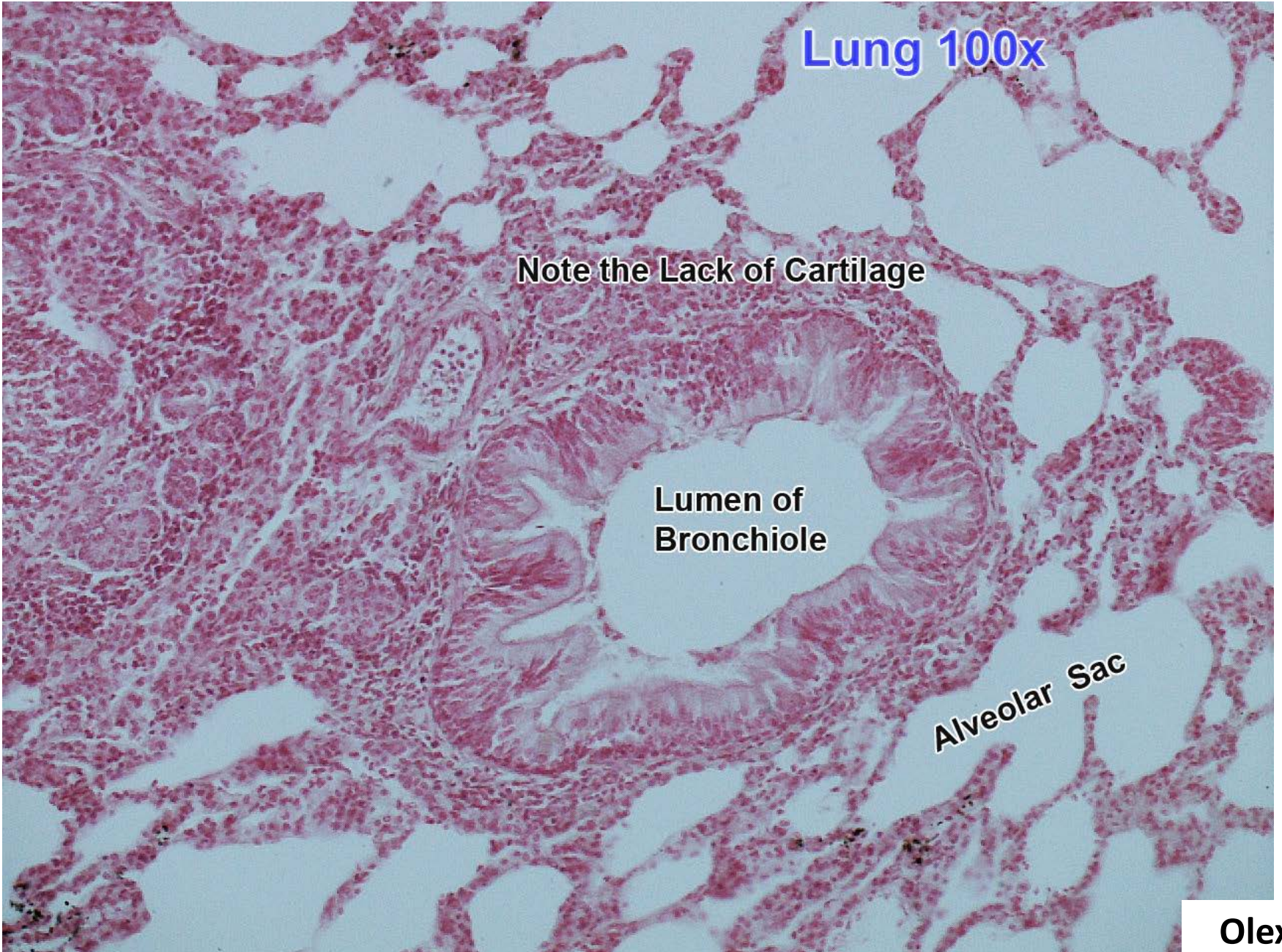


Lung 100x

Note the Lack of Cartilage

**Lumen of
Bronchiole**

Alveolar Sac



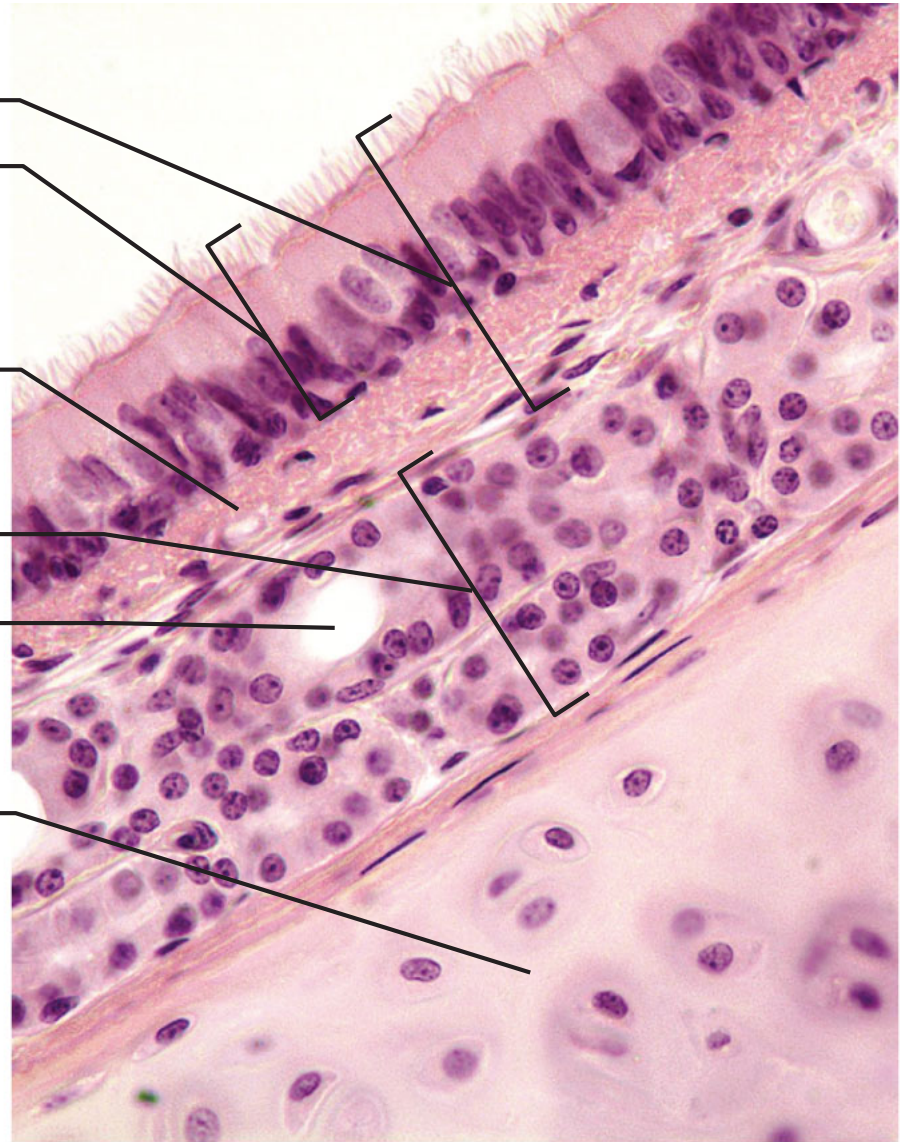
Mucosa

- **Pseudostratified ciliated columnar epithelium**
- **Lamina propria (connective tissue)**

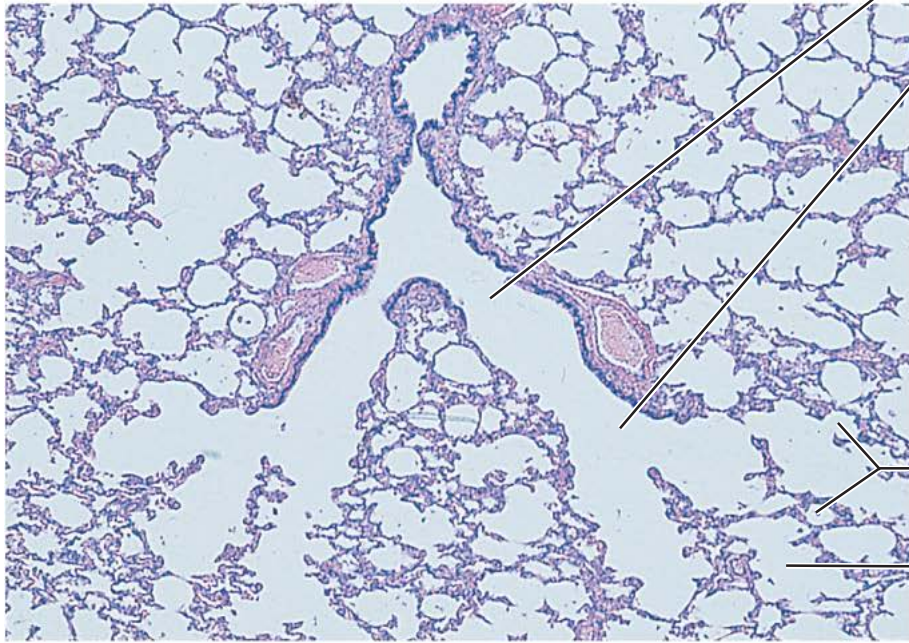
Submucosa

Seromucous gland in submucosa

Hyaline cartilage



(b) Photomicrograph of the tracheal wall (320x)

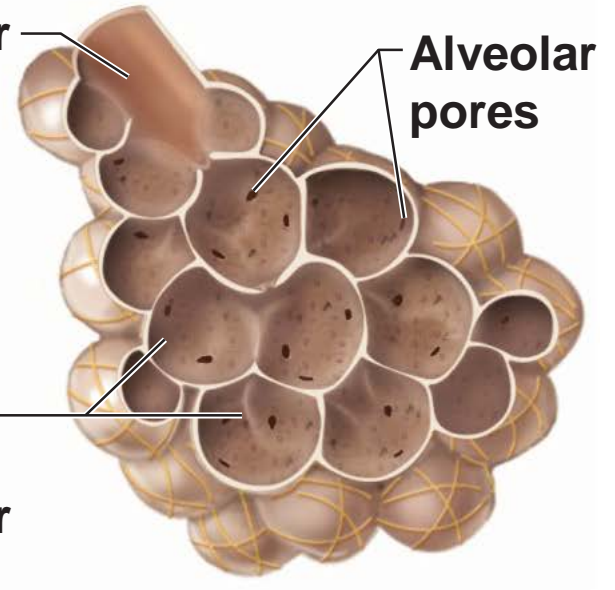


**Respiratory
bronchiole**

**Alveolar
duct**

Alveoli

**Alveolar
sac**

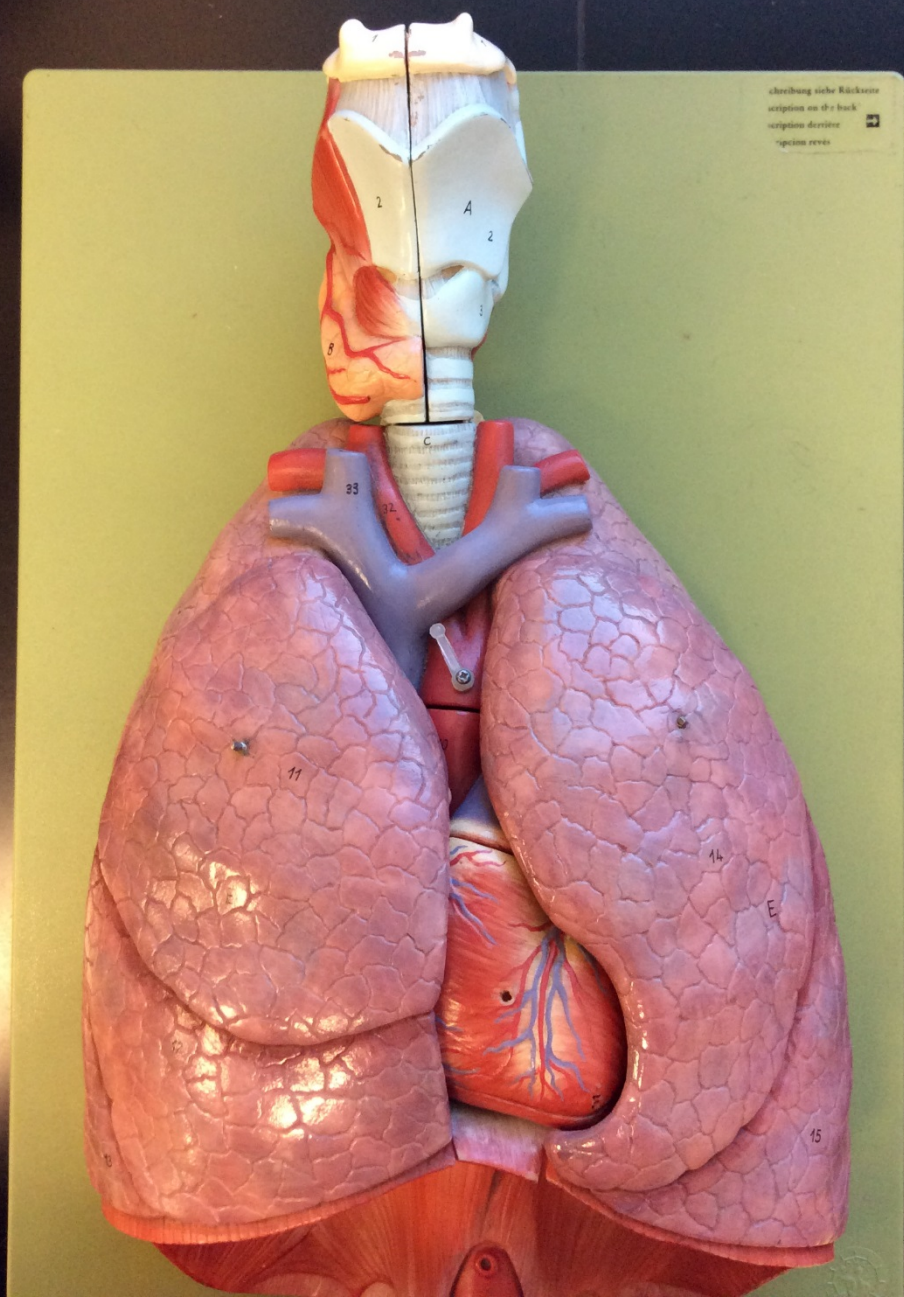


**Alveolar
pores**

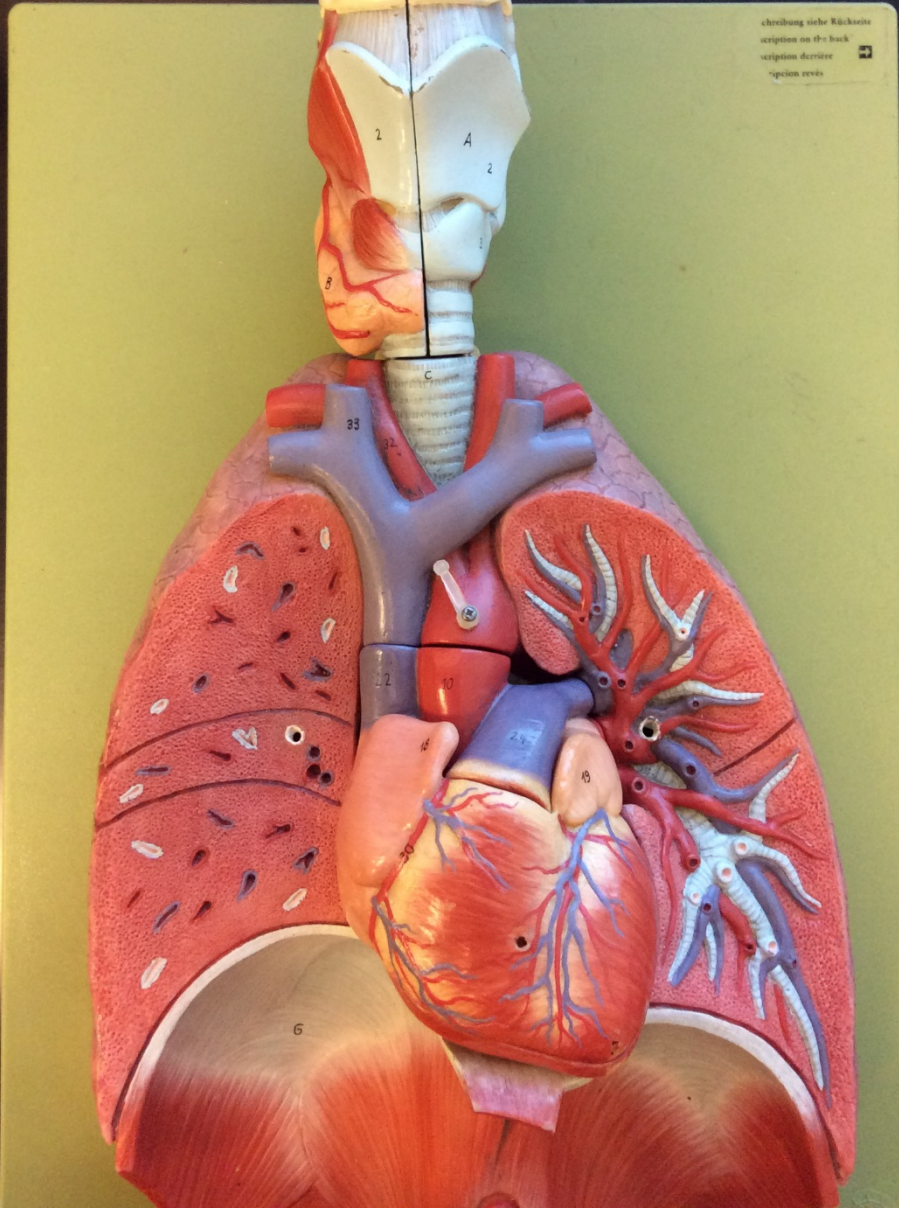
(b)

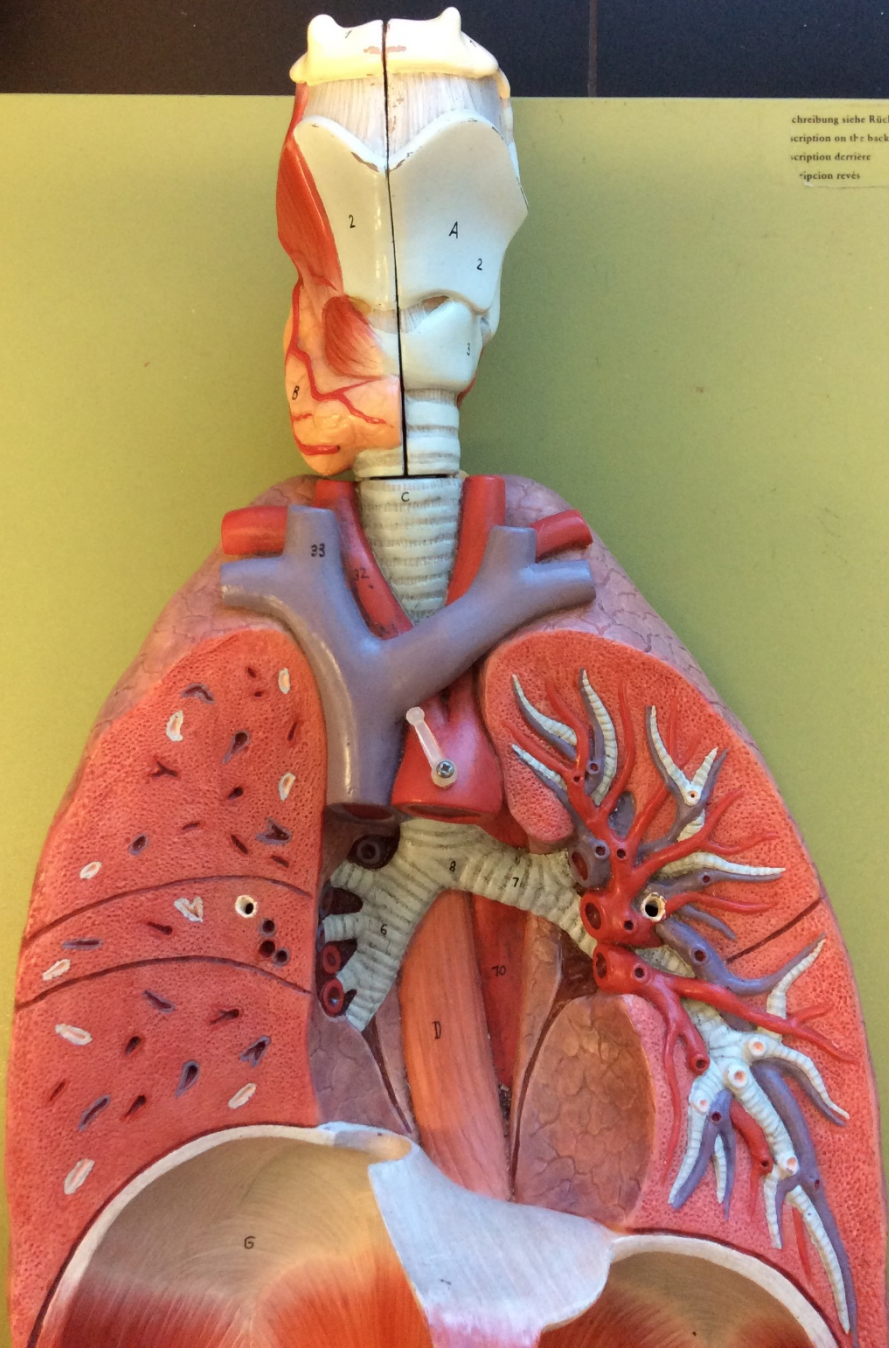
Use the following pictures to help you practice finding the terms from the lab term handout on unlabeled images.

- Remember, you won't learn them if you don't take plenty of time to practice on pictures with NO labels (including no labels for what type of slide it is on histology pictures)!
- Also, be sure to mix up the order once you get comfortable with the unlabeled slides.
- Over the weekend, once you are feeling confident with the pictures here, do the histology quizzes in PAL (from the Pearson website) to get practice with new pictures that you haven't seen.

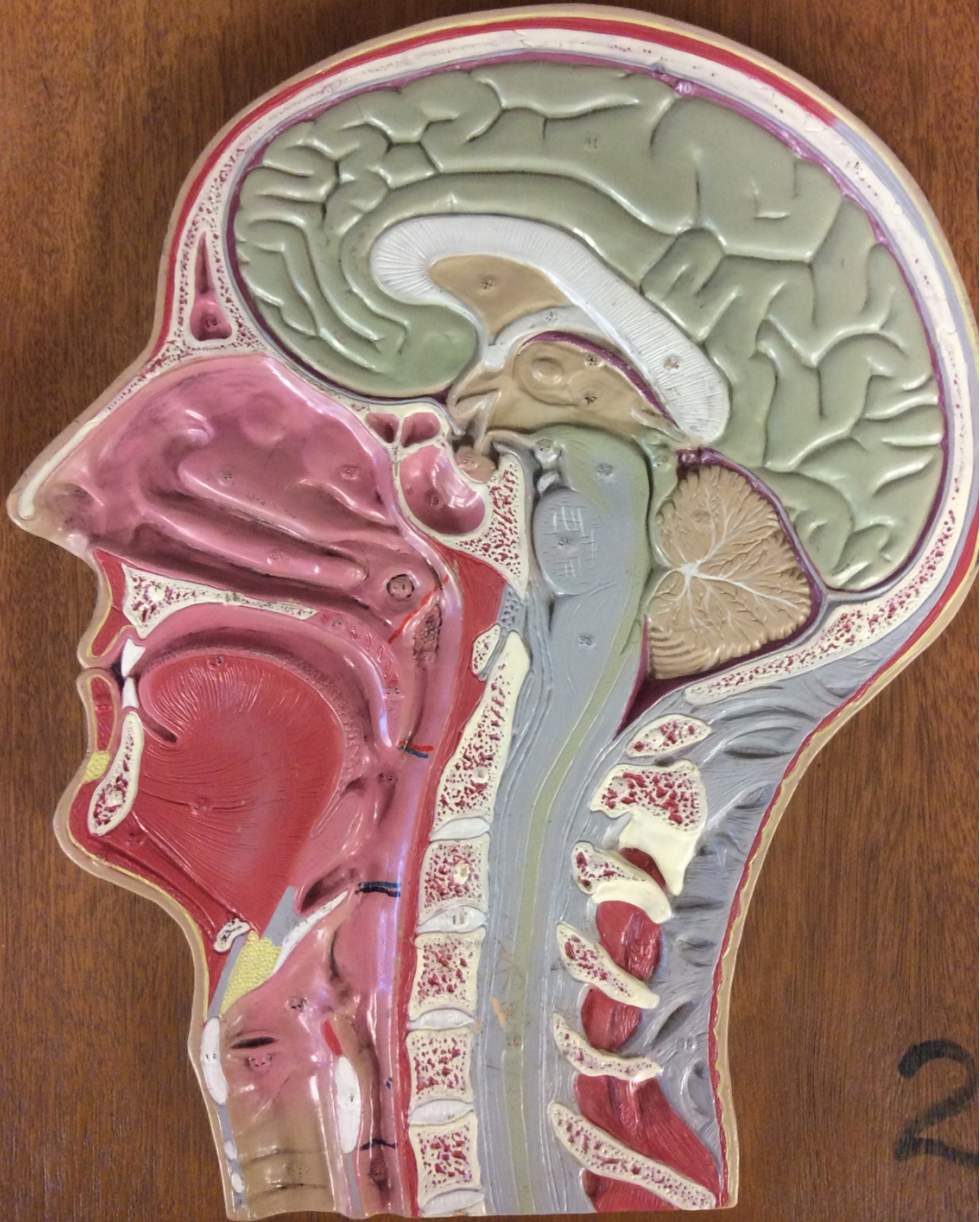

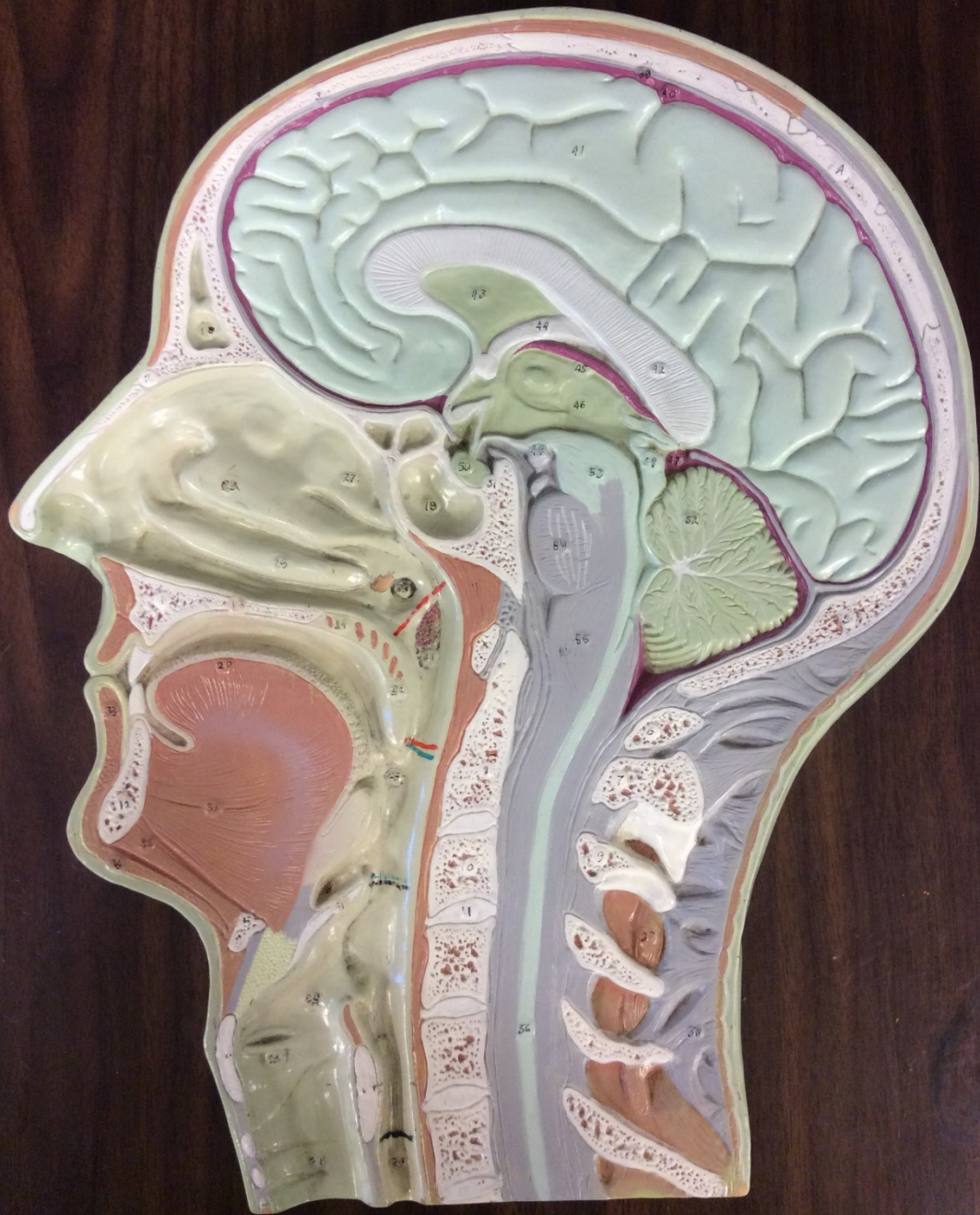Schreibung siehe Rückenansicht
Description on the back
Description dorsale
"specimen reverso"

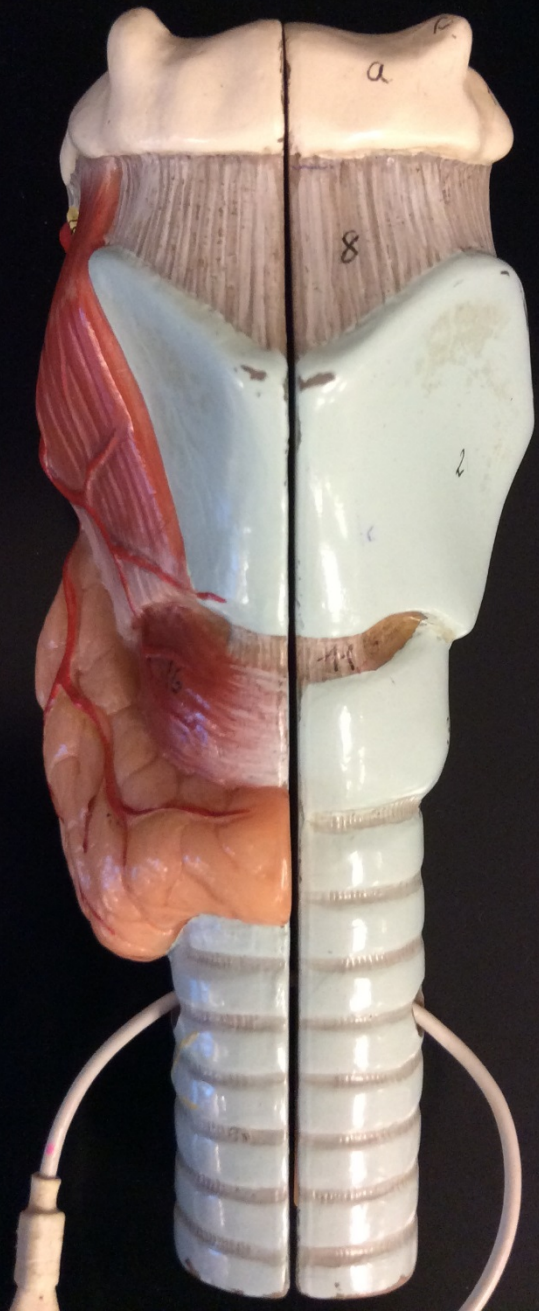


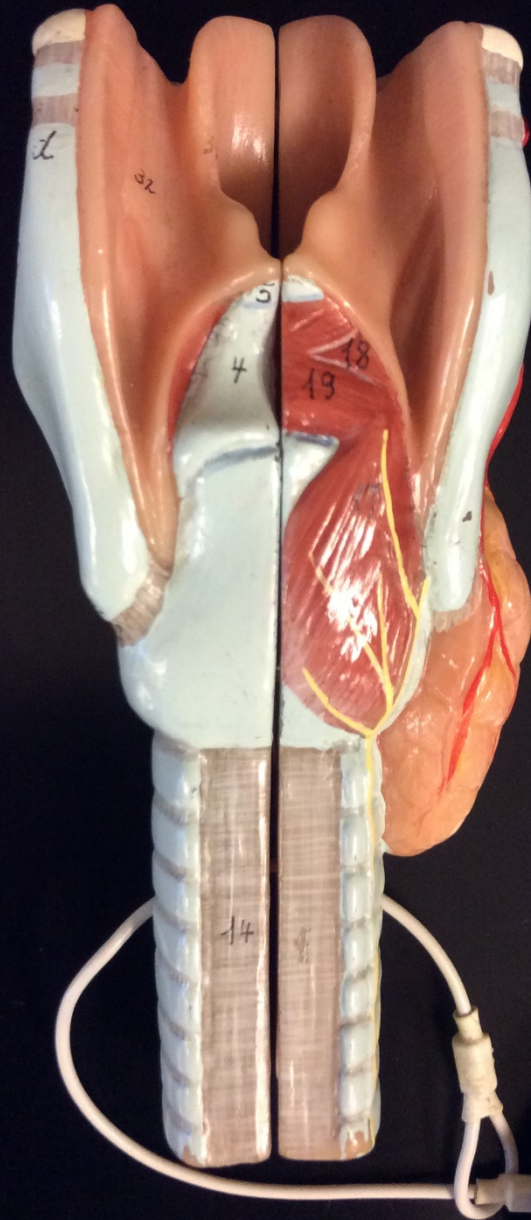


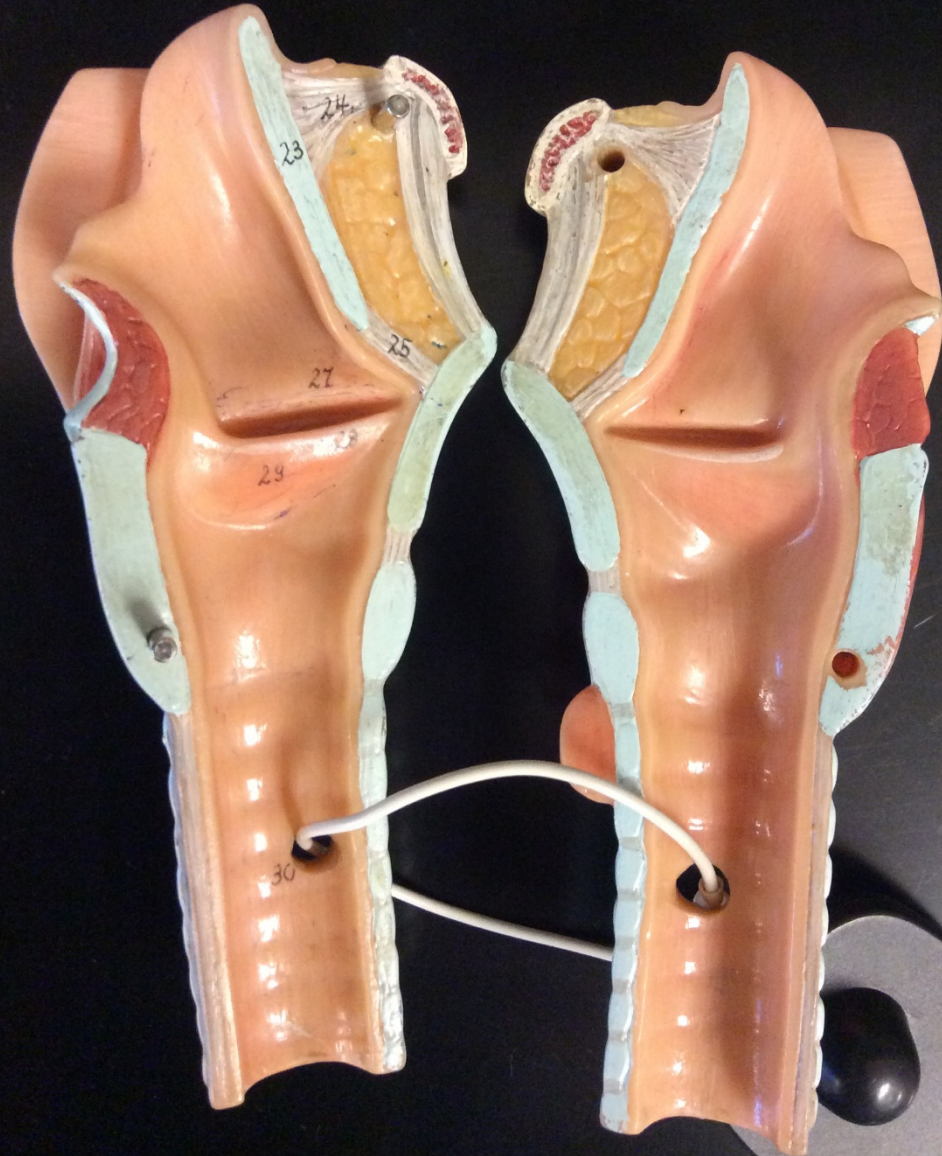beschreibung siehe Rückseite
description on the back
description derrière
description revers

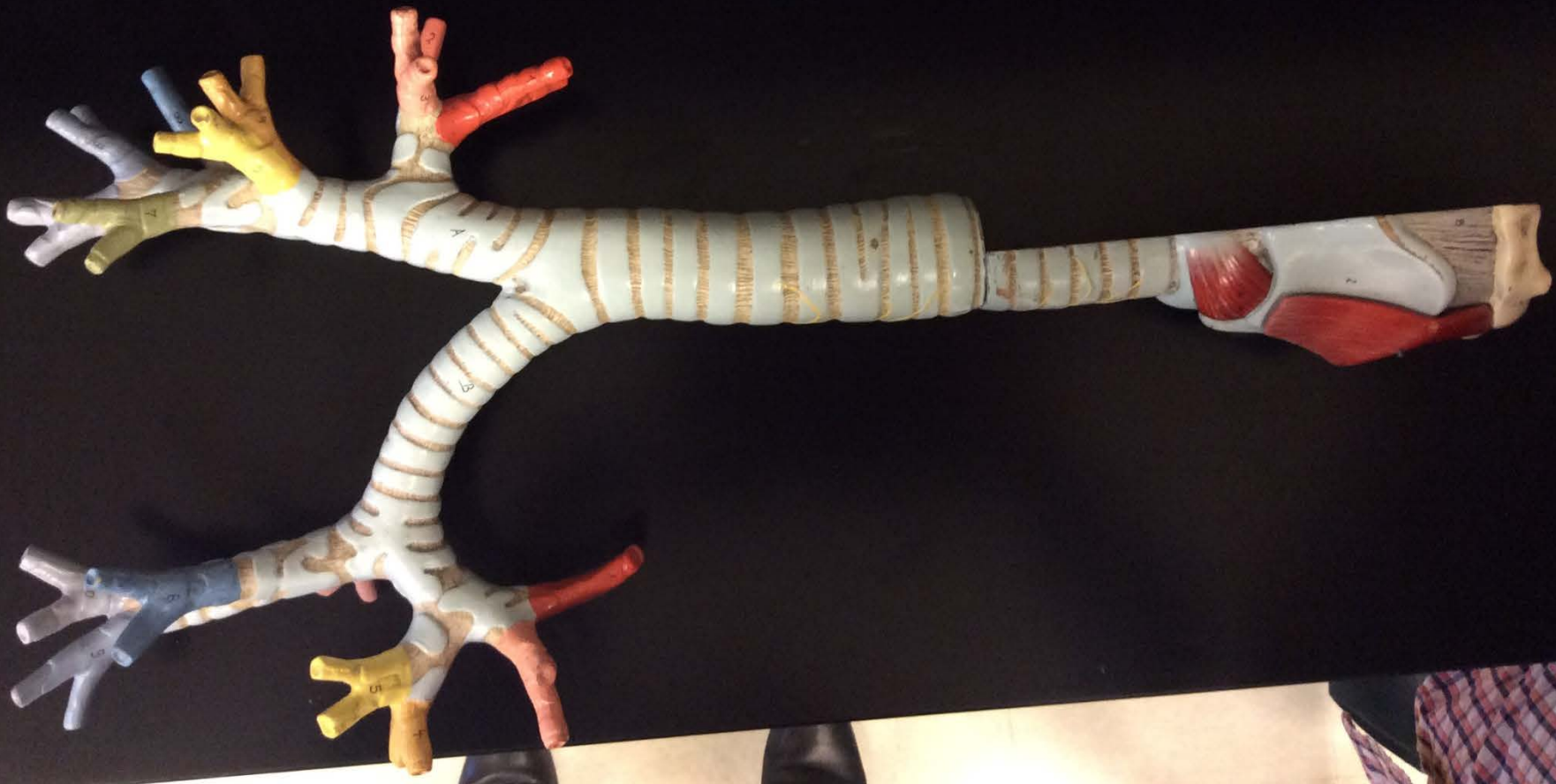

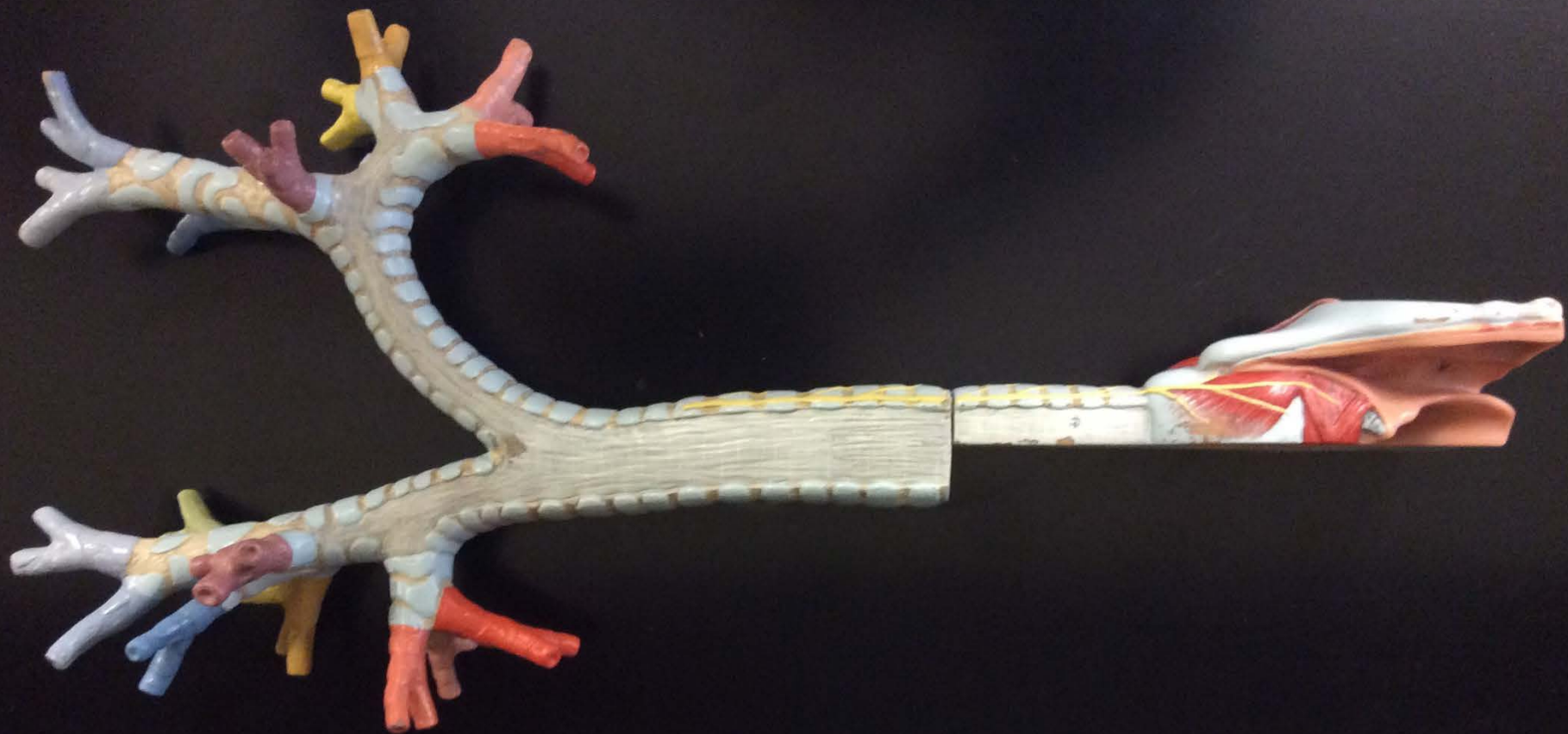


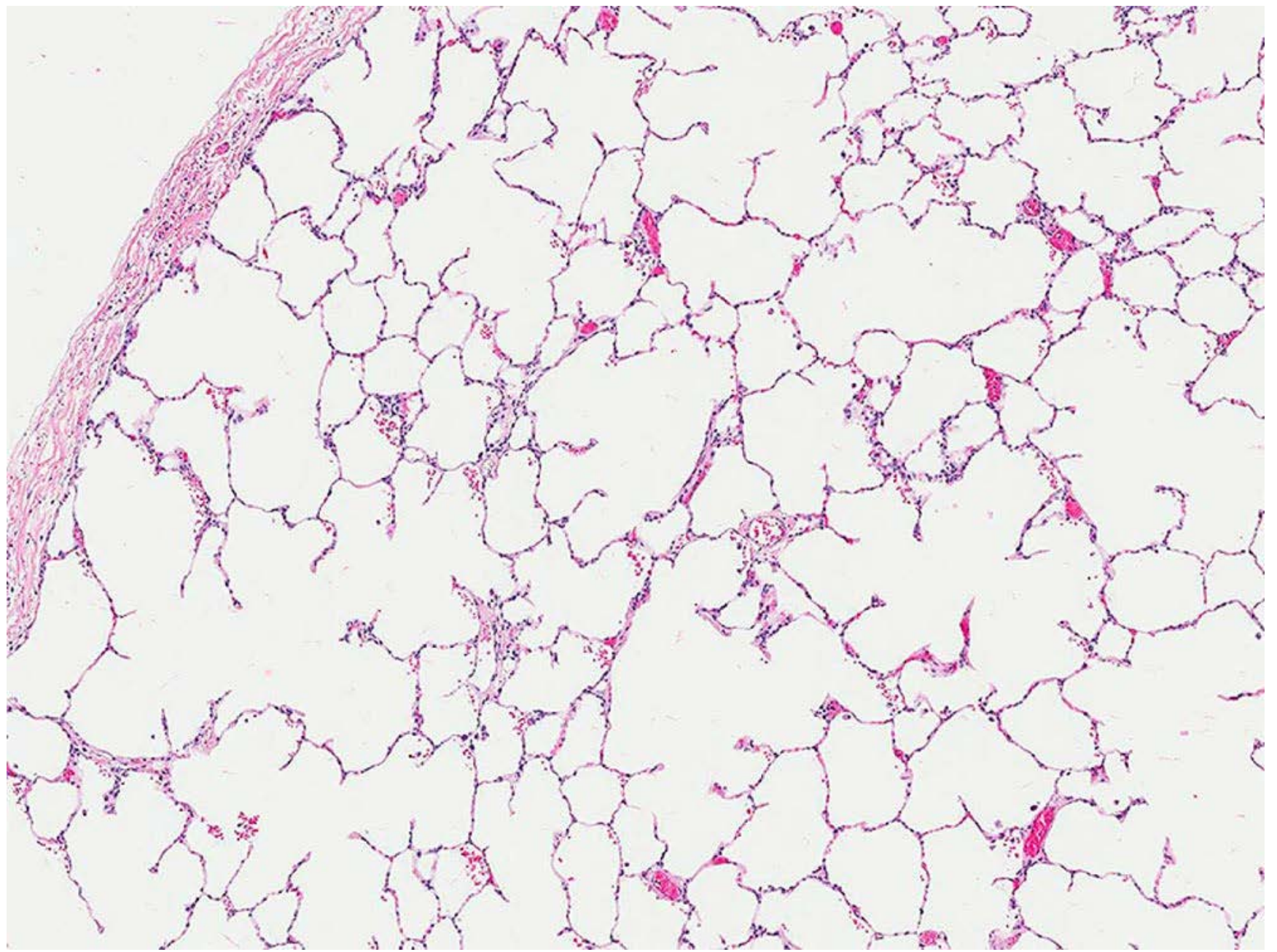


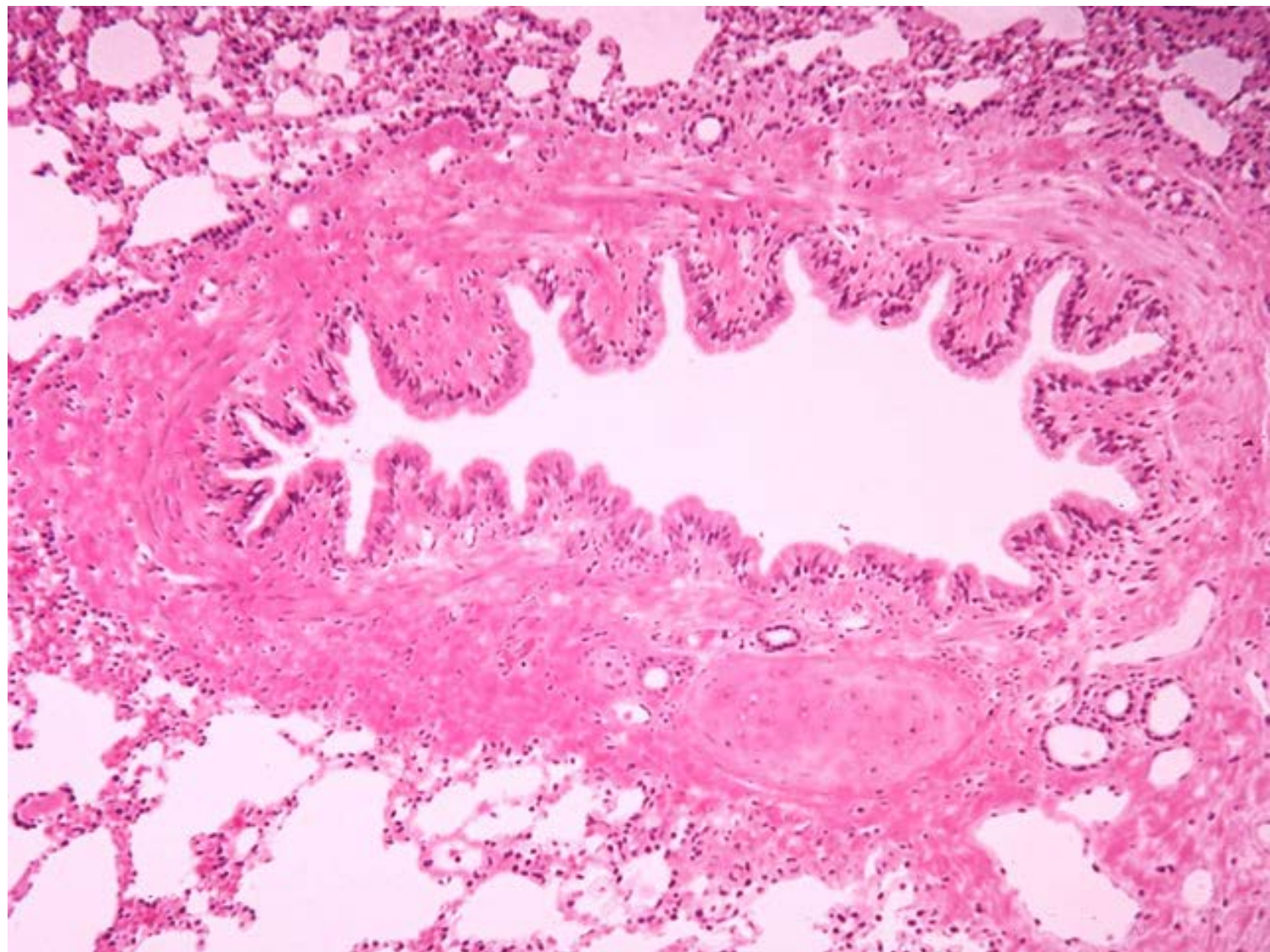


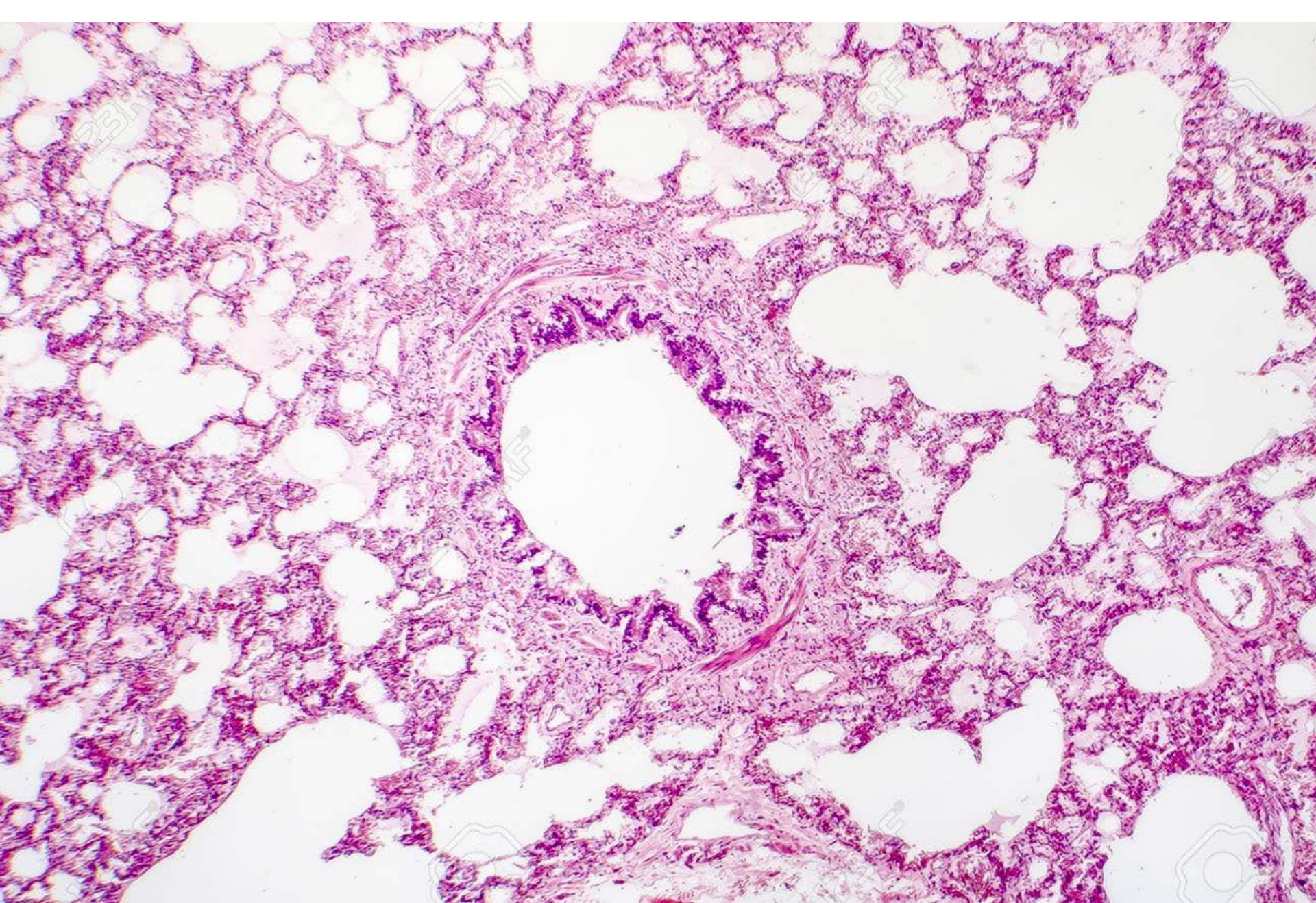


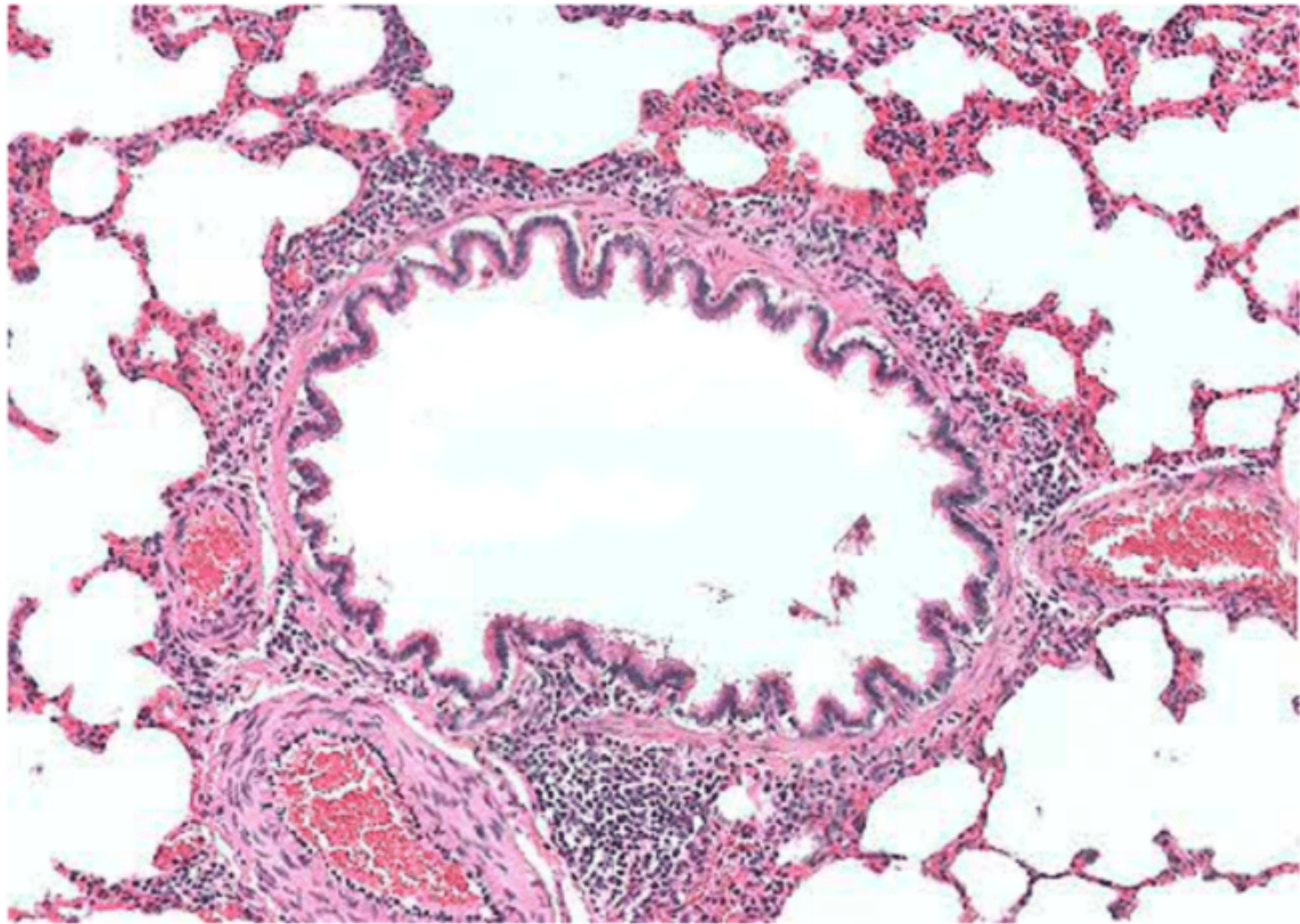


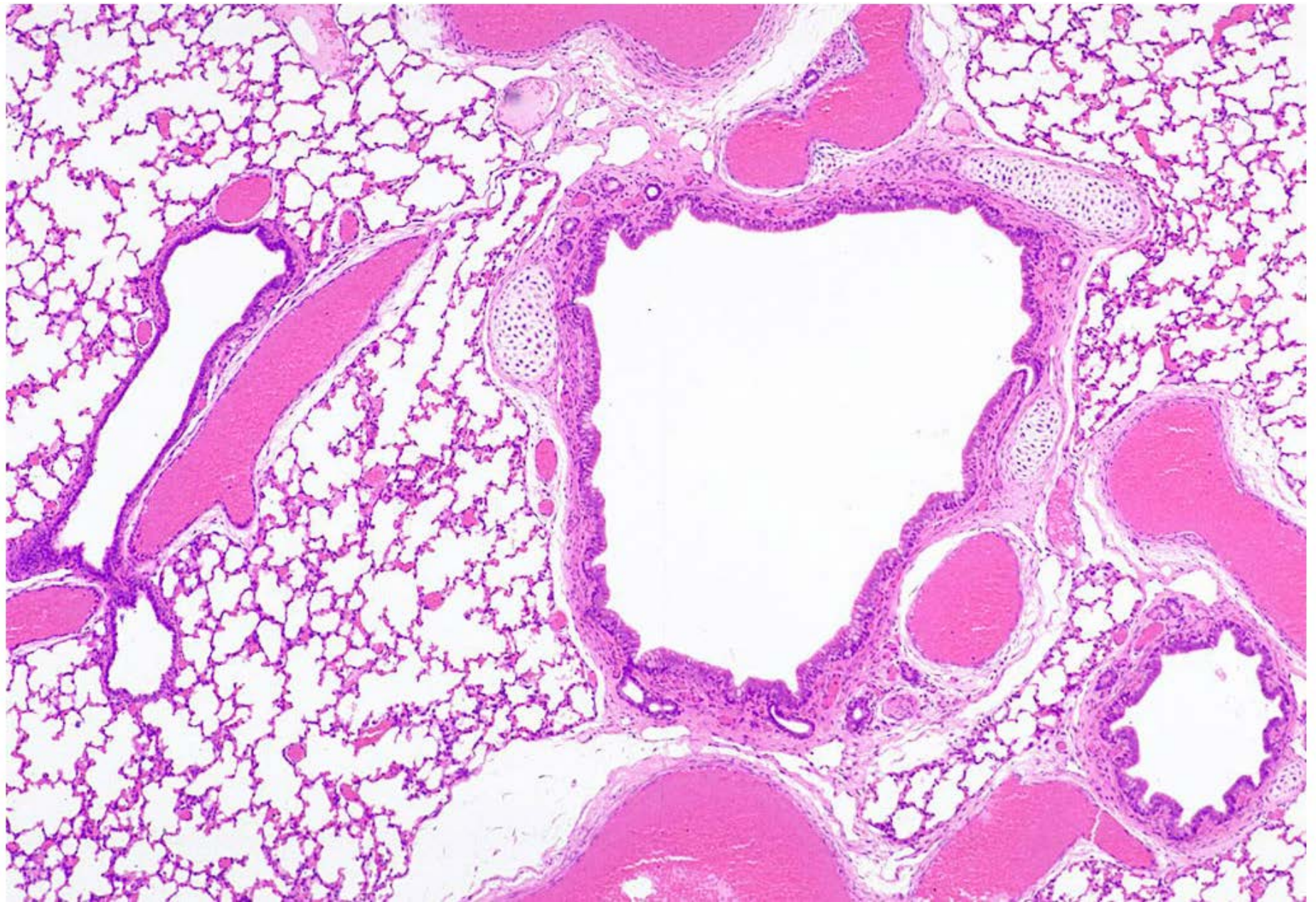






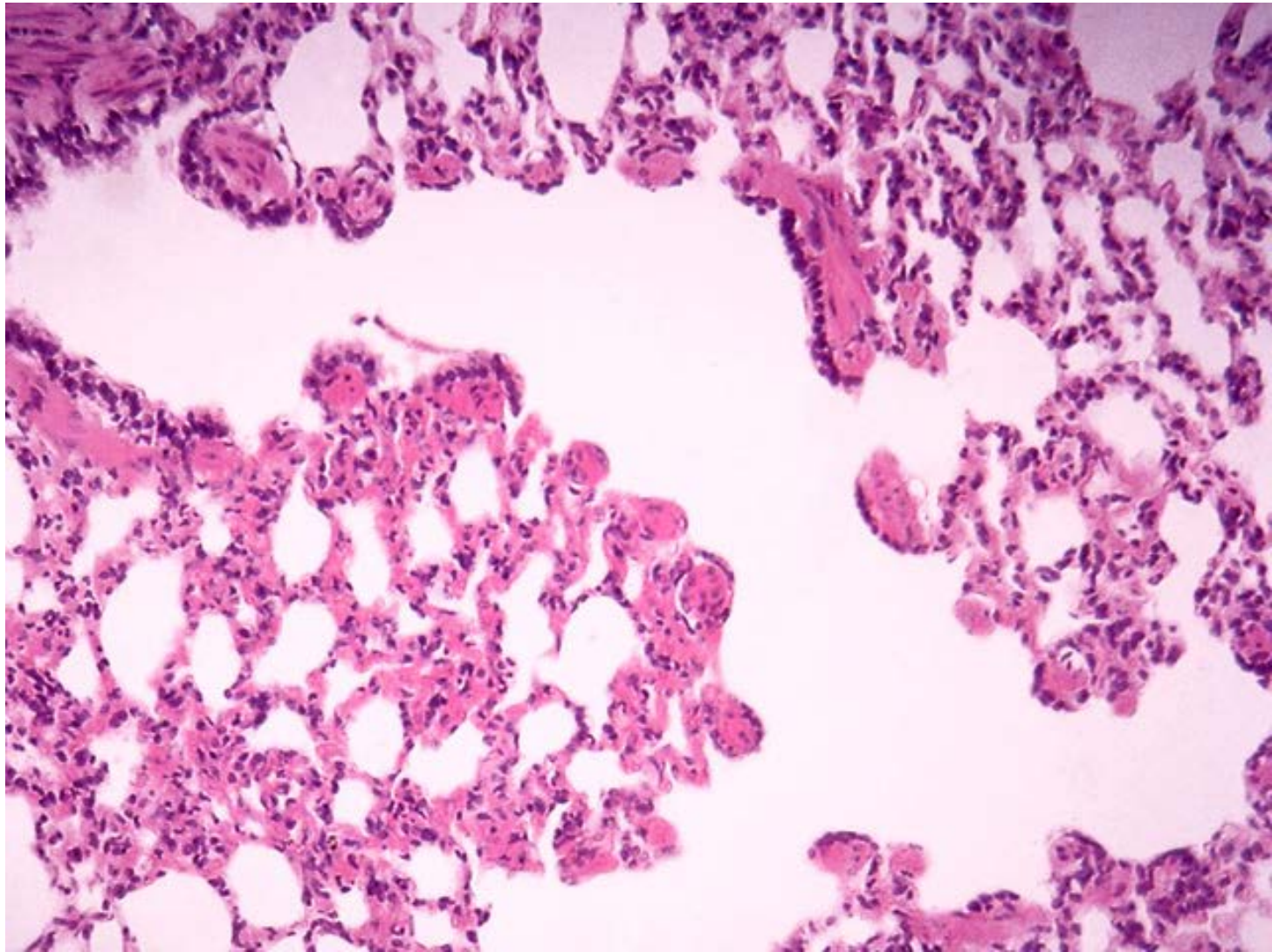


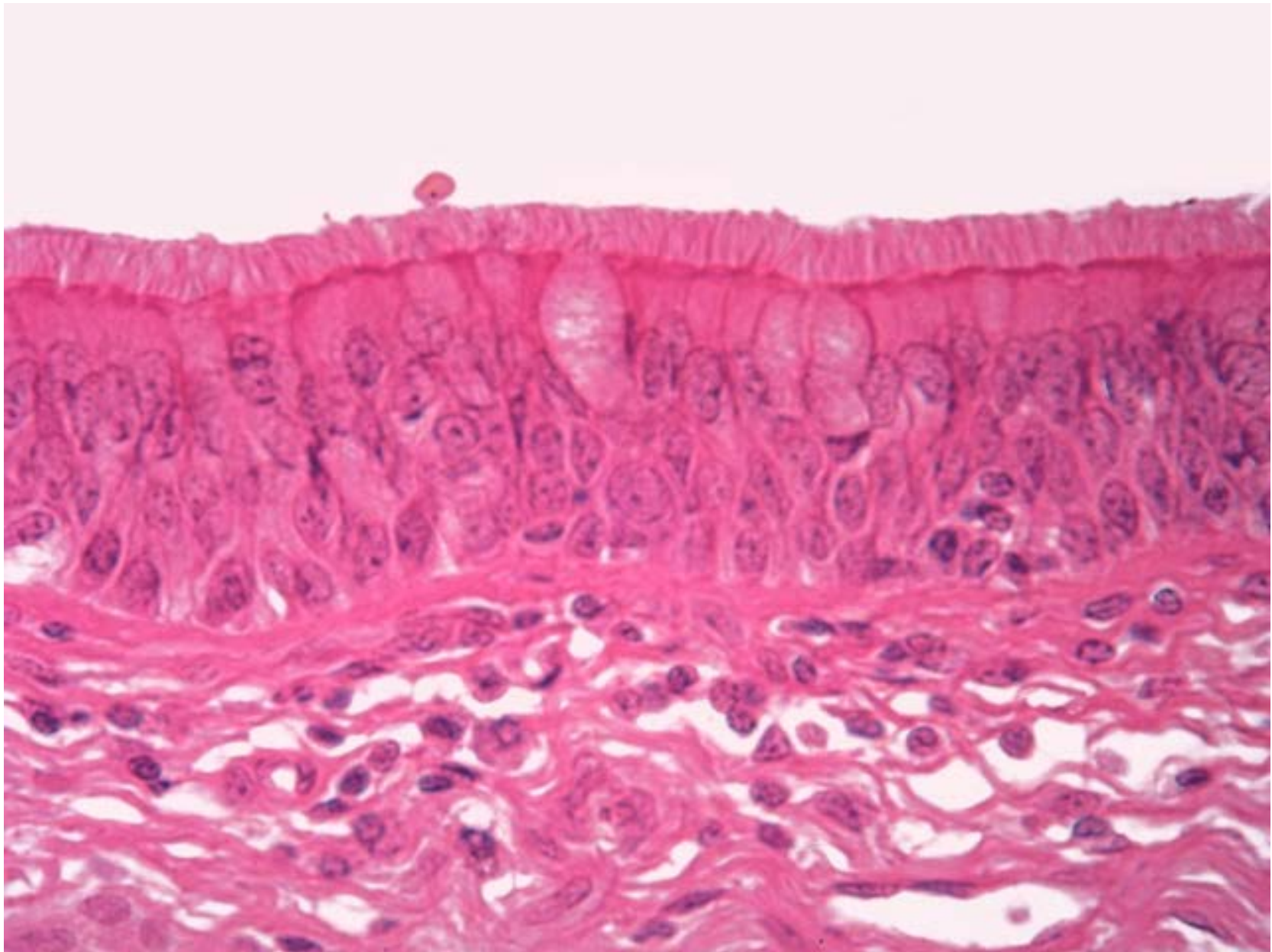




Website with interactive labels:

http://medcell.med.yale.edu/histology/respiratory_system_lab/intrapulmonary_air_conduits.php





Website with interactive labels:

<https://medpics.ucsd.edu/index.cfm?curpage=image&course=hist&mode=browse&lesson=45&img=863>

Respiratory virtual microscope:

http://aperio.duhs.duke.edu/UMichHistology/Respiratory/130_HISTO_20X.svs/view.apml?

http://141.214.65.171/Histology/Respiratory%20System/132_HISTO_20X.svs/view.apml?

http://141.214.65.171/Histology/Respiratory%20System/132_HISTO_40X.svs/view.apml?

****Make sure Adobe Flash Player is enabled for this website.**